

Performance Comparison of Urine Sediment Analytical Tool by Flowcytometry and Digital Imaging with Standardized Manual Microscopic Testing

Nur Fitri Hayati Melida Ritonga¹, Ferdy R. Marpaung¹, Hartono Kahar¹, Nunuk Mardiana², Yessy Puspitasari^{1,*}

**Nur Fitri Hayati Melida Ritonga¹,
Ferdy R. Marpaung¹, Hartono
Kahar¹, Nunuk Mardiana², Yessy
Puspitasari^{1,*}**

¹Department of Clinical Pathology Dr Soetomo Academic Hospital/Faculty of Medicine Universitas Airlangga Surabaya, INDONESIA.

²Department of Internal Medicine Dr Soetomo Academic Hospital/Faculty of Medicine Universitas Airlangga Surabaya, INDONESIA.

Correspondence

Yessy Puspitasari

Department of Clinical Pathology Dr Soetomo Academic Hospital/Faculty of Medicine Universitas Airlangga Surabaya, INDONESIA.

E-mail: yessy.puspitasari@fk.unair.ac.id

History

- Submission Date: 11-10-2023;
- Review completed: 21-11-2023;
- Accepted Date: 29-11-2023.

DOI : 10.5530/pj.2023.15.216

Article Available online

<http://www.phcogj.com/v15/i6>

Copyright

© 2023 Phcogj.Com. This is an open-access article distributed under the terms of the Creative Commons Attribution 4.0 International license.

ABSTRACT

Background: Urine sediment examination provides numerous information about patient's kidney condition. Flowcytometry and digital imaging system could conduct automatic urine sediment analysis. Therefore, determining the diagnostic performance of the examination is very important in the management carried out by the clinician. This study aims to determine the diagnostic performance of urine flowcytometry and digital imaging sediment examination tools compared to manual microscopes that are standardized as gold standards. **Methods:** This study is an analytical observational study with a cross-sectional approach on 92 urine samples of patients who attended the Internal Medicine Nephrology Polyclinic of Dr. Soetomo Academic Hospital Surabaya. The performance of flowcytometry and digital imaging methods is assessed by calculating sensitivity and specificity. Analysis of the suitability of each urine sediment parameter used Cohen's kappa. Urine sediment analysis with a light microscope was conducted with the Shih-Yung method as a gold standard. **Results:** The erythrocyte parameters revealed a very favorable result with the concordance of the flowcytometry with the Shih-Yung method ($\kappa=0.82$) and fair results for WBC ($\kappa=0.25$), Epithelium ($\kappa=0.57$) and Cast ($\kappa=0.27$). At the same time, yeast had substantial conformity ($\kappa=0.63$). The digital imaging method showed substantive fit for WBC ($\kappa=0.676$), RBC ($\kappa=0.621$), fair for SEC ($\kappa=0.42$) and NSE ($\kappa=0.24$), moderate for Yeast ($\kappa=0.45$), and slight for Hyaline Cast ($\kappa=0.074$) and Path Cast ($\kappa=0.134$). **Conclusion:** The urine flowcytometry demonstrates better performance compatibility with a standardized manual microscope compared to urine digital imaging. However, pathological samples should still be verified with a manual microscope.

Key words: Urine sediment, Microscopic, Flowcytometry, Digital imaging.

INTRODUCTION

Urine sediment examination provides numerous information about the condition of the patient's kidneys and is a biomarker in the urine, which could help clinicians to discover the presence of kidney disease, and damage to the renal compartment, as a therapeutic guide and determine the patient's prognosis¹⁻³.

Urine sediment examination could provide information about certain particles that could aid in urinalysis result interpretation⁴⁻⁶. Abnormality in urine sediments, such as casts, crystals, and microorganisms⁷, could be seen in urine sediments with kidney disruption and urinary tract. Still, the presence of renal tubular cells, red blood cell (RBC) casts, white blood cell (WBC) casts, coarse granular casts, broad casts, and dysmorphic RBCs in a significant number could be a pathognomonic of suspicion towards kidney disruption⁸⁻¹¹.

In the attempt to automatize microscopic urine analysis, many urine sediment analysis systems have been developed since the late 80s¹². Automatic sediment urine analysis is based on its principle, and its function is divided into flowcytometry and digital imaging systems. Flowcytometry-based analysis classifies urine particles based on forward-scattered light, side-scattered light and side fluorescence light characteristics¹³. Digital imaging-based analysis utilized much imaging from a digital camera combined with an automatized particle reading software¹. However, urine

sediment analysis has several limitations, such as lack of precision and standardization, lack in sensitivity and specificity; thus, urine sediment examination with a manual microscope is still considered the "gold standard"^{2,14}.

Previous studies by Enko D et al. and Kucukgergin et al. revealed a difference in sensitivity and specificity between the urine sediment automatic instruments with flowcytometry and digital imaging systems^{1,15}. However, the authors have not found a study about urine sediment experiments with digital imaging utilizing FUS-1000. Thus, we wish to understand how compatible the urine sediment examination instrument using Sysmex UF-5000 with FUS-1000 is compared to the manual microscope standardized as the gold standard. An excellent and compatible urine sediment examination could aid in kidney condition evaluation and determination of the patient's following therapy. In addition, this automatic examination is expected to shorten routine medical check-up times and standardized examinations.

Therefore, this study aims to determine the association between urine sediment flowcytometry, digital imaging instruments, and standardized manual microscope in the patient's urine samples.

MATERIAL AND METHODS

Urine specimen

The research design was analytically studied with a cross-sectional approach, starting from October

Cite this article: Ritonga NFHM, Marpaung FR, Kahar H, Mardiana N, Puspitasari Y. Performance Comparison of Urine Sediment Analytical Tool by Flowcytometry and Digital Imaging with Standardized Manual Microscopic Testing. *Pharmacogn J.* 2023;12(6): 1189-1196.

2021 to March 2022. A total of 1967 patients visited the Internal Medicine Nephrology Polyclinic of Dr. Soetomo Academic Hospital. Still, only patients requested urinalysis testing during the study period at the Central Laboratory Dr. Soetomo Academic Hospital. Urine samples were collected in sterile containers, then screened using a UC-3500 analyzer (Sysmex, Kobe, Japan). Only three parameters were used for screening criteria which were positive for one parameter, including erythrocytes, leukocytes, and protein. Inclusion criteria included patients over 18 years of age, abnormal routine urine analysis results, and urine samples analyzed within 2 hours. Exclusion criteria were urine samples less than 25 mL. Based on the inclusion criteria, 92 urine samples met the urine sediment analysis criteria using UF-5000 (Sysmex, Kobe, Japan), FUS -1000 (Dirui Industrial Co., LTD, China), and standardized manual microscopy (Figure 1). Patients who participated in this study were explained the research procedure and signed informed consent. This research was approved by the Ethics Committee of RSUD Dr. Soetomo Surabaya with Ethics Number: 0627/126/III/2021.

Automatic Urine Sediment Analysis

UF-5000

The principle of examination is by using the flowcytometry method, emitting a laser to the particles in the urine and analyzing the results of scattered light and fluorescent light to determine the type or characteristics of a particle or cell. This tool has two inspection channels, the SurFace (SF) and CoRe (CR) channels, each having different functions. The SF channel functions as a urine material meter that does not contain a nucleus, while the CR channel functions as a urine material meter that has a nucleus. Parameter analysis includes Red Blood Cell (RBC), White Blood Cell (WBC), Squamous Epithelial cell (SEC), Non-Squamous (NSEC), Casts; Hyaline CAST, Pathological CAST (Path Cast), Bacteria (BACT), Crystals (X^TTAL), Yeast-like cells (YLC), Spermatozoa (SPERM), MUCUS^{16,17}. A 0.45 mL device then aspirated a 2 mL urine sample, and the sample will experience dilution (125 μ L sample and 362.5 μ L diluent). Results will be in the form of numbers, scattergrams, and histograms¹⁶. This study uses seven parameters: Red Blood Cell (RBC), White Blood Cell (WBC), Squamous Epithelial cell (SEC), Non-Squamous (NSEC), Casts; Hyaline CAST, Pathological CAST (Path Cast), Yeast-like cells (YLC).

FUS 1000

The working principle adopts the Flowing Microscopy Imaging System, with two layers of a sheath on the outside; the sample enters the system after aspiration. The mechanical flow system of the tool is composed of specially designed thin disc layers. Under two sheath layers, the urine sample enters the flow cell as a single-cell layer. Each image will be photographed at high speed. Artificial intelligence identification technique: the visible components of each photo will be separated by a kind of grid. Computer software with highly trained intelligence can quickly photograph the visible components of a urine sample and classify them by shape, texture, and frequency domain characteristics. The components seen in the photographs will be classified into 12 categories, namely: Red Blood Cell (RBC), White Blood Cell (WBC), White Blood Cell Cluster (WBCC), Squamous Epithelial Cell (SQEP), Non-Squamous Epithelial Cells (NSE), Hyaline (HYAL), Pathological cast (UNCC), Bacteria (BACT), Yeast (BYST), Sperm (SPRM), and Mucus strands (MUCS). Single particles that cannot be included in the 12 categories above are included in the unclassified (UNCL) category. To differentiate and assess pathological crystal and cast categories, the operator must manually confirm the photograph from the screen¹⁸. FUS-1000 requires 2 mL of sample to be aspirated¹⁸. This study uses seven parameters: Red Blood Cell (RBC), White Blood Cell (WBC), Squamous Epithelial Cell (SQEP), Non-Squamous Epithelial Cells (NSE), Hyaline (HYAL), Pathological cast (UNCC), Yeast (BYST).

Standardized Manual Microscope

Microscopic examination of urine must provide correct identification of the different particles and accurate measurement of their amount, requiring standardization of the methods used. It is essential to increase the accuracy and limit of detection independently of the desired final performance level. Some investigators have advocated examination of the urine sediment collected in the counting chamber because the large volume of counting results in a more precise count and possibly higher sensitivity compared to non-centrifuged specimens. Standard procedures using phase-contrast microscopy or supravital stains are recommended for particle identification.^{10,12,19}

This study examined urine sediment with a light microscope using the Shih-Yung method without staining for quantitative calculations of RBC, WBC, epithelium, cast, and yeast. The Shih-Yung method consists of a counting chamber, a scaled centrifuge tube (12 ml in size), and a sediment dropper pipette (1 ml in size)^{20,21}. First, the urine was centrifuged and tube is quickly inverted (decanting) to remove the supernatant so that the remaining the sediment (0.6 ml remaining) was put into the counting chamber. Specimens were examined first with a magnification of 100x to see cells, then with a magnification of 400x for the parameters of erythrocytes, leukocytes, epithelium, and yeast counted at ten fields of view, the number of sediment elements was reported quantitatively per microliter of urine. For calculations without coloring with Factors = $n \times 1/0.20 \times 1/20 = 0.25n$. The reference value of urine sediment by the Shih-Yung method; erythrocytes (Normal: $< 3/\mu$ L, Abnormal: $> 3/\mu$ Lcy), leukocytes (Normal: $< 10/\mu$ L, Abnormal: $> 10/\mu$ L), Epithelium (Male : $0-1/\mu$ L, Female : $0-9/\mu$ L), Cast (Normal : $0/\mu$ L, Abnormal: 1 or $> 1/\mu$ L), Yeast (Normal : $0/\mu$ L, Abnormal: 1 or $> 1/\mu$ L). The results will be read by three officers who are experts and experienced in assessing urine sediment with a low-light condenser microscope¹⁹⁻²¹.

Phase-contrast microscopy

The phase contrast microscope used in this study is an Inverted Microscope. Urine was transferred into a tube of 5-12 mL and then centrifuged at 2000 rpm for 5 minutes. The supernatant was decanted so that the remaining sediment was resuspended with 0.3-0.5 mL of the remaining supernatant, then placed one drop of urine was on a glass object and covered with a covered glass. The percentage of dysmorphic erythrocytes was calculated by looking at the appearance of dysmorphic erythrocytes at 400x magnification in 10 fields of view. Counted the amount of visual field 0-2; 2-5; 5-10; 10-25; 25-50; 50-99; > 100 per large field of view (LPB), and the result is divided by the lower limit of the grouping results of the erythrocyte count and multiplied by 100%^{1,22,23}. The results will be read by three officers who are experts and experienced in assessing urine sediment with a phase contrast microscope.

Data Analysis

The data obtained were analyzed to examine the performance of urine sediment instruments flowcytometry and digital imaging by comparing the gold standard Shih Yung method with Open Epi Software. Analysis of suitability was with Cohen's kappa analysis. According to Landis and Koch (1977) kappa score category was $0.00 < \kappa < 0.20$ slight, $0.21 < \kappa < 0.40$ fair, $0.41 < \kappa < 0.60$ moderate, $0.61 < \kappa < 0.80$ substantial, and $0.81 < \kappa < 1.00$ is almost perfect agreement. $p < 0.05$ was significant statistically.

In the study, the cut-off values used for each parameter were as follows; RBC $\geq 3 \mu$ L, WBC $\geq 5 \mu$ L, SQUAMOUS-EPITHELIUM (male $> 1,40 \mu$ L; female $> 5.80 \mu$ L) NON SQUAMOUS EPITHELIUM (male $> 2,22 \mu$ L; female $> 2.63 \mu$ L, HYALINE CAST (male $> 0 \mu$ L; female $> 0 \mu$ L), PATH CAST (male $> 0 \mu$ L; female $> 0.13 \mu$ L), YEAST (male $> 0 \mu$ L; woman $> 0.10 \mu$ L)²¹.

RESULTS

Diagnostic performance analysis from the flowcytometry automatic urine sediment analysis instrument and urine digital imaging with a standardized manual microscope was conducted on 92 urine samples from the subjects of this study. The examination result was then categorized according to the predetermined rules to gain performance from each instrument. Below is the profile description and the examination results from the study samples.

Patient demography

The median value of the study subject was 51 years old (ranging between 18-81 years old), with 56.5% male and 43.5% female. The most frequent disease encountered was Chronic Kidney Disease (CKD), with 46.7%, followed by Nephrotic Syndrome, as much as 26.1%. A total of 26% of the patients were without comorbidities; the most common comorbidities were diabetes mellitus followed by hypertension. We also summarized the incidence of clinical manifestations of hematuria and leukocyturia, classification based on microscopic features and associated with disease diagnosis. Hematuria and leukocyturia are frequently seen in patients with chronic kidney disease (Table 1).

Diagnostic Examination

Furthermore, a diagnostic examination was conducted to compare the flowcytometry and digital imaging urine sediment instrument performance with the gold standard, Shih Yung, using Open Epi software. The diagnostic examination was conducted using the result data of each category that was determined before each instrument. The diagnostic examination results are as follows (Table 2).

From Table 2, the diagnostic examination performance of flowcytometry is slightly better than digital imaging. In the flowcytometry instrument, it was known that the highest sensitivity was 94.87% in the WBC parameter. This result showed that the ability of flowcytometry to detect WBC (+) with a cut-off value of $\geq 5 /\mu\text{l}$ is 95.77% and detect RBC (+) with a cut-off value $\geq 3 /\mu\text{l}$ is 91.78%, and also highest sensitivity was 95.92% in the yeast parameter. The other examination results with flowcytometry had the highest specificity being 82,76 in the Epithel SE parameter. The highest PPV (positive predictive value) for flowcytometry was 93.06% in the RBC parameter, showing the proportion between the sample with erythrocyte value (+). Furthermore, for NPV (negative predictive value) of flowcytometry was highest at 92.75% in the Cast parameter.

The diagnostic result of digital imaging had the highest sensitivity value 92.31%, in the WBC parameter. This result showed that the ability of the digital imaging instruments to detect leukocyte (+) with the same cut of value $\geq 5 /\mu\text{l}$ was 92.96%. digital imaging had PPV (positive predictive value) with the highest percentage of 91.04% in the RBC parameter. The highest NPV (negative predictive value) was 91.04% in the Path Cast parameter.

Cohen kappa consistency examination

Diagnostic examination results that had been conducted were then continued by performing the Cohen Kappa test to examine the consistency of flowcytometry and digital imaging examination results compared to the gold standard of Shih Yung. The complete result of the Cohen Kappa examination is explained in Table 3 below.

The analysis result of Cohen Kappa in the flowcytometry and Digital imaging instruments was generally considered meaningful, except for the consistency of the Cast examination using digital imaging and yeast in flowcytometry.

Bland - Altman plots were performed to evaluate differences between UF-5000, FUS-1000, and Shih - Yung. Parameter RBC, WBC, NSE,

and SE RBC, WBC, NSE, and SE parameters, hyaline cast, path cast, and yeast the plots are within the upper and lower lines, respectively, indicating no difference in the results of Sysmex and Shih-Yung and FUS-1000 with Shih-Yung (Figures 2-5).

Flagging Sysmex UF-5000

As many as 52 (56.5%) samples from 92 urine samples were positive for RBC with the manual microscope. From that result, 66 samples were isomorphic, three were dysmorphic (>20% dysmorphic) and three samples were RBC Mixed. According to Table 4, UF-5000 was marked 16/92 (17.3%) Flag RBC - info ("isomorphic?", "dysmorphic?", "mixed?"), compared to the contrast phase microscope. "isomorphic?" RBC flag showed 9/10 (90%) and "dysmorphic?" RBC flag 2/3 (66.7%) in the microscopic urine sediment examination. A total of 3 flag RBC-Info "dysmorphic" samples were shown by UF-5000, whereas one sample was identified in the isomorphic pattern with the manual microscope.

Using the cut-off $> 20\mu\text{l}$ for RBCs on the UF-5000 device, *RBC dysmorphic* flagging will appear and needs to be reviewed using phase contrast microscopy. We also tried to find a match between the RBC flagging in the device and phase contrast microscopy, and the kappa value 0.652 showed substantial.

DISCUSSION

Urine analysis is essential for patient examination in screening, diagnosis, and treatment plans. The utilization of an automatic urinalysis system could save time and energy^{1,8,10,14,19}. In this study, both methods revealed high sensitivity for WBC, whereas, for RBC parameters, the digital imaging method showed lower sensitivity compared to flowcytometry. Enko et al. reported similar results with a low sensitivity for RBC, with an error in the classification of interference of particles or other cells being the possible reason¹. RBC cell recognition in the automatic sediment analysis instrument often needs to be improved, especially in urine samples^{1,8}. Correct RBC identification is difficult because of dysmorphic erythrocytes, ghost RBCs, or yeast classification errors²⁴. Besides that, other possible sources of errors include a variation of focused field, clumped cells, or particle identification errors that could cause bias^{25,26}.

Flowcytometry revealed a higher sensitivity than digital imaging for the SE, NSE, Hyaline, Path cast, and yeast parameters¹¹. However, the specificity is quite high for NSEC, Hyaline cast, Path cast and Yeast parameters compared to flowcytometry method. The Kappa value was fair for yeast and epithelial parameters. The difference in cell analysis method between flowcytometry and digital imaging could be a potential reason^{2,15}. In this study, the digital imaging method revealed a falsely high value for yeast parameters. After confirmation with a manual microscope, there was an error in the identification of sperms that were considered yeast; thus, confirmation with a manual microscope is still considered to be essential. The cause of the difference still needed to be clarified; there were several causes, such as working/storage of samples, cell loss in centrifugation, and inaccurate manual count^{24,25,27}.

The cast significantly impacts clinically, with challenging identification in all automatic systems. The hyaline cast could be found in both physiologic and pathologic conditions. In contrast, pathological casts always reveal pathologic conditions^{24,25}. This study revealed that the sensitivity of cast is high in the flowcytometry method and high specificity in the digital imaging method. Mucus, fibers, WBC clumps, hypha, and contamination caused the false positive result²⁵. The false negative result was caused by elements lysed in an old sample, diluted, and preserved. Increased specificity was correlated with decreased interference of mucus and WBC clumps²⁵.

In this study, collecting positive hyaline and pathological cast samples was difficult, so a larger number of samples were needed further to

Table 1: Patient characteristic.

Characteristic	n (%)	Characteristic	n (%)
Age (year)		Sex	
18-28	18 (19.6%)	Male	52 (56.5%)
29-38	10 (10.9%)	Female	40 (40.3%)
39-48	15 (16.3%)		
49-58	21 (22.8%)	Clinical Manifestation	
59-68	16 (17.4%)	Hematuria	
69-78	11 (12.0%)	Bladder Carcinoma	2 (2.2%)
>78	1 (1.1%)	Ureterolithiasis	1 (1.1%)
Diagnosis		Chronic Kidney Disease	34 (35.9%)
Bladder Carcinoma	2 (2.2%)	Renal Hypertension	1 (1.1%)
Ureterolithiasis	1 (1.1%)	Polycystic Kidney Disease	1 (1.1%)
Chronic Kidney Disease	44 (46.7%)	Glomerular Disease	5 (2.2%)
Renal Hypertension	2 (2.2%)	Hypocalcemia	1 (1.1%)
Polycystic Kidney Disease	2 (2.2%)	Urinary Tract Infection	3 (3.3%)
Glomerular Disease	7 (3.3%)	Polynuropathy Diabetic	2 (2.2%)
Hypocalcemia	2 (2.2%)	Nephrotic Sydnrome	1 (1.1%)
Urinary Tract Infection	5 (5.4%)	Systemic Lupus Erythematosus	22 (23.9%)
Polynuropathy Diabetic	2 (2.2%)		
Nephrotic Sydnrome	24 (26.1%)	Leukosituria	
Systemic Lupus Erythematosus	1 (1.1%)	Bladder Carcinoma	2 (2.2%)
Comorbid		Ureterolithiasis	1 (1.1%)
No comorbid	24 (26.1%)	Chronic Kidney Disease	37 (39.1%)
DM Type 2	23 (25.0%)	Renal Hypertension	2 (2.2%)
DM Type 2 + Hypertension	20 (21.7%)	Polycystic Kidney Disease	2 (2.2%)
DM Type 2 + Hypertension+ Atherosclerosis	2 (2.2%)	Glomerular Disease	6 (3.3%)
DM Tipe 2 + Atherosclerosis	1 (1.1%)	Hypocalcemia	1 (1.1%)
Hypertension	19 (20.7%)	Urinary Tract Infection	5 (5.4%)
SLE	1 (1.1%)	Polineuropathy Diabetic	1 (1.1%)
DM Tipe 2 + SLE	2 (2.2%)	Nephrotic Sydnrome	1 (1.1%)
		Systemic Lupus Erythematosus	14 (15.2%)

Table 2: Diagnostic examination results.

Variabel	Flowcytometry				Digital Imaging			
	Sensi (%)	Speci (%)	PPV (%)	NPV (%)	Sensi (%)	Speci (%)	PPV (%)	NPV (%)
RBC	91.78	73.68	93.06	70.00	83.56	68.42	91.04	52.00
WBC	95.77	42.86	85.00	75.00	92.96	61.90	89.19	72.22
SEC	79.41	82.76	72.97	87.27	73.53	70.69	59.52	82.00
NSEC	92.31	55.70	25.53	97.78	38.46	87.34	33.33	89.61
Hyaline Cast	84.00	40.30	34.43	87.10	36.00	71.64	32.14	75.00
Path Cast	81.82	54.32	19.57	95.65	45.45	75.31	20.00	91.04
Yeast	95.92	13.95	55.95	75.00	40.82	88.37	80.00	56.72

Note: RBC: Red Blood Cell, Path cast: Pathological cast, SE: Squamous Epithelial Cell, NSEC:Non- Squamous Epithelial Cell.

Table 3: Cohen Kappa analysis urine sediment parameter between flowcytometry and digital imaging.

Parameter	Flowcytometry			Digital imaging		
	Cohen's Kappa	CI 95%	P value	Cohen's Kappa	CI 95%	P value
RBC	0.642	0.438 – 0.846	< 0.001	0.466	0.264 – 0.667	< 0.001
WBC	0.455	0.262 – 0.648	< 0.001	0.578	0.374 – 0.781	< 0.001
SEC	0.611	0.407 – 0.814	< 0.001	0.422	0.221 – 0.623	< 0.001
NSE	0.229	0.089 – 0.370	0.001	0.243	0.039 – 0.446	0.020
Hyaline	0.167	0.018 – 0.317	0.028	0.074	-0.130 – 0.277	0.479
Path Cast	0.152	0.029 – 0.284	0.024	0.134	-0.047 – 0.315	0.146
Yeast	0.103	-0.018 – 0.225	0.094	0.282	0.106 – 0.458	0.002

Note: RBC: Red Blood Cell, Path cast: Pathological cast, SE: Squamous Epithelial Cell, NSEC:Non- Squamous Epithelial Cell.

Table 4: Flagging Sysmex UF-5000.

Flagging Sysmex UF-5000	Phase Contrast Microscopic			Kappa	Total
	Isomorphic	Dysmorphic	Mixed		
Isomorphic	66	0	0	0.652	66
Dysmorphic	1	2	0		3
RBC Mixed	3	0	0		3

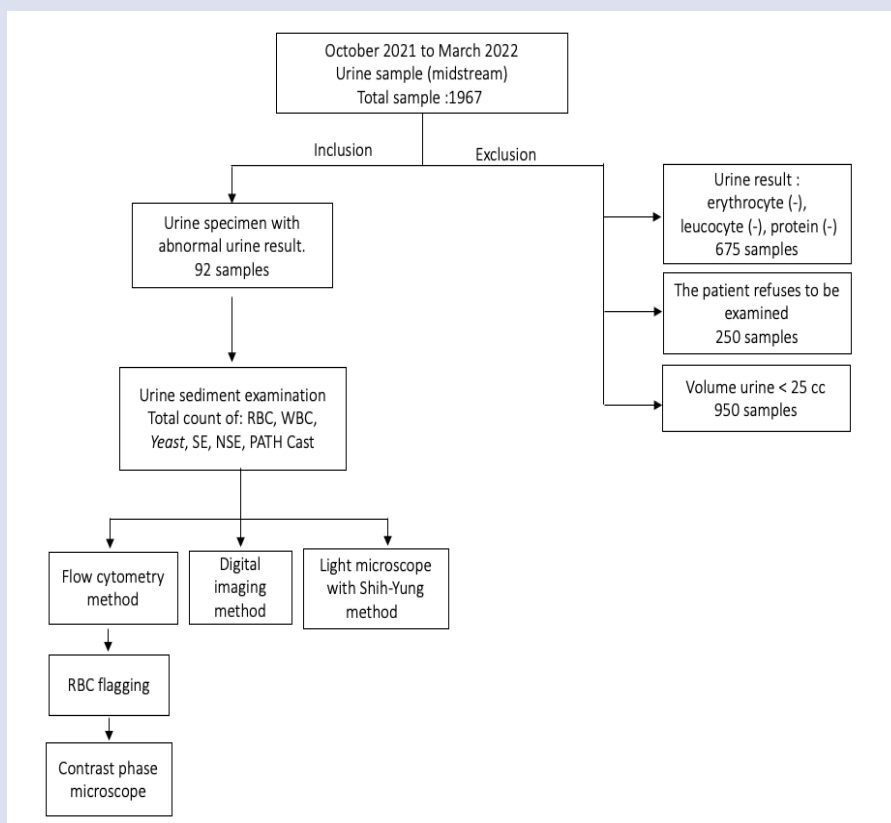


Figure 1: Sample analysis experiment scheme.

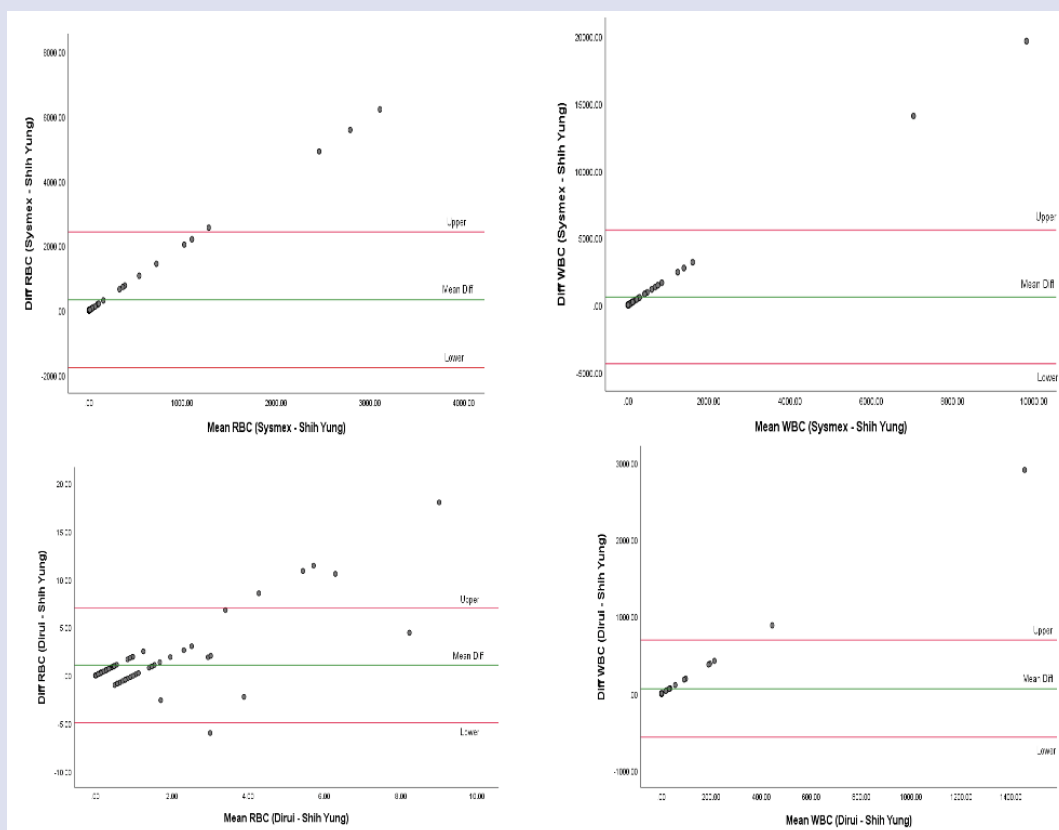


Figure 2: Bland Altman analyses of RBC, WBC UF-5000 (Sysmex), FUS-1000 (Dirui) and Shih – Yung.

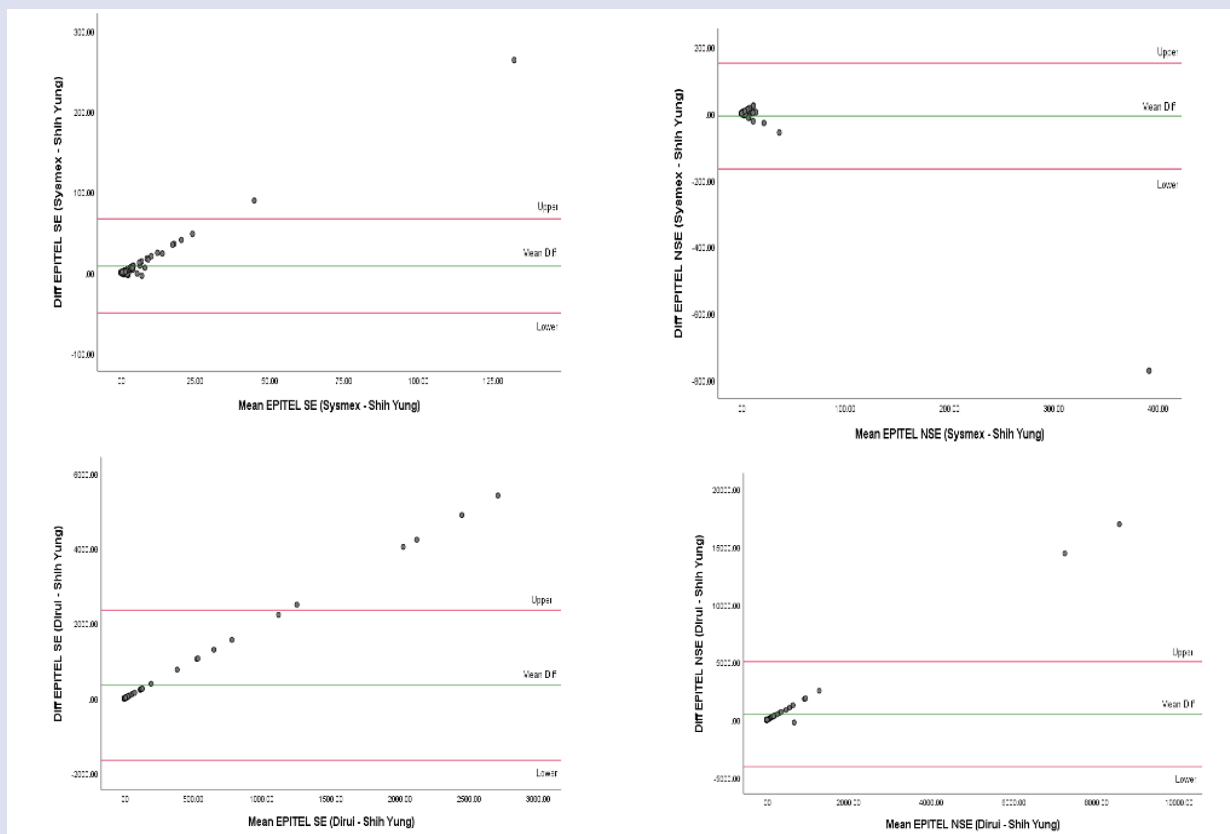


Figure 3: Bland Altman analyses of SE: Squamous Epithelial Cell, NSEC: Non- Squamous Epithelial Cell UF-5000 (Sysmex), FUS-1000 (Dirui) and Shih – Yung.

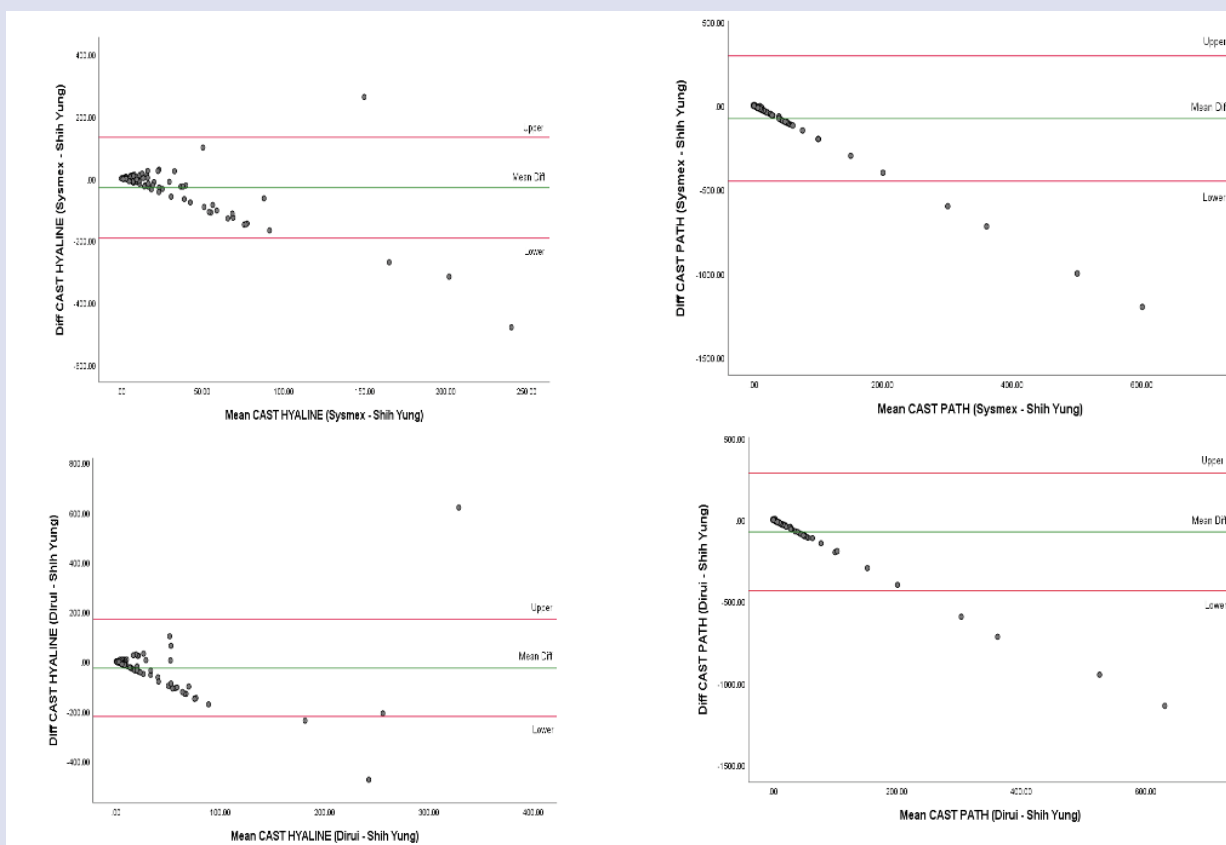


Figure 4: Bland Altman analyses Hyaline cast and Pathological Cast UF-5000 (Sysmex), FUS-1000 (Dirui) and Shih – Yung.

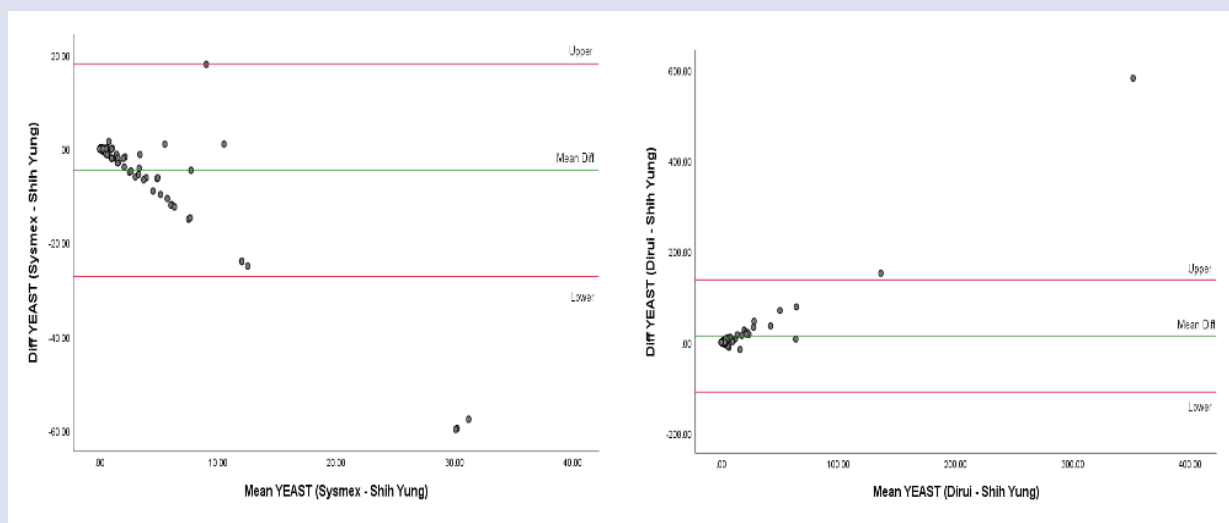


Figure 5: Bland Altman analyses Yeast Flocytometry, digital imaging and Shih – Yung.

confirm the differences in casts between the two methods. The ability of an instrument to detect epithelial and classify them into the renal tubular cell is of paramount importance because this cell is sensitive to portray tubular damage when ischemic or in toxic injuries. In this study, the epithelial parameter in digital imaging had a lower sensitivity because of the difference in the cell detection method of each instrument.^{1,27} In this study, the number of pathological samples in the dysmorphic and isomorphic RBC flags was scarce. It thus could not portray the comparison between the flowcytometry and contrast phase microscope methods. The contrast phase microscope is a gold standard for dysmorphic erythrocyte examination. It is essential to check the automatic RBC info sign with a manual microscope because detecting dysmorphic RBC in the urine is an essential diagnostic tool to identify individuals with glomerulus diseases^{1,22,28}. Evaluation of erythrocyte morphology in urine has been widely used to determine the diagnosis of glomerular or non-glomerular diseases diagnosis^{29,30}.

Automatic urine analysis has several advantages and disadvantages. The benefits are increased precision and believable results, with many samples processed quickly compared to manual analysis. In addition, the automatic instrument could store data for analysis and comparison in the future. On the other hand, in the digital imaging method, the analysis result is shown as pictures but still needs a manual microscope to confirm. In contrast, in the flowcytometry method, pictures were not included. Therefore, the disadvantage of flowcytometry and digital imaging methods is an increased cost.

The strength of this study is that it uses the Shih-Yung counting chamber to standardize the number of cells, making it more precise and detailed. The limitation of this study is that the population was limited to the Kidney outpatient clinic of the Internal Department. Also, in this finding, we found a small number of dysmorphic RBC, cast, and epithelial to analyze.

CONCLUSION

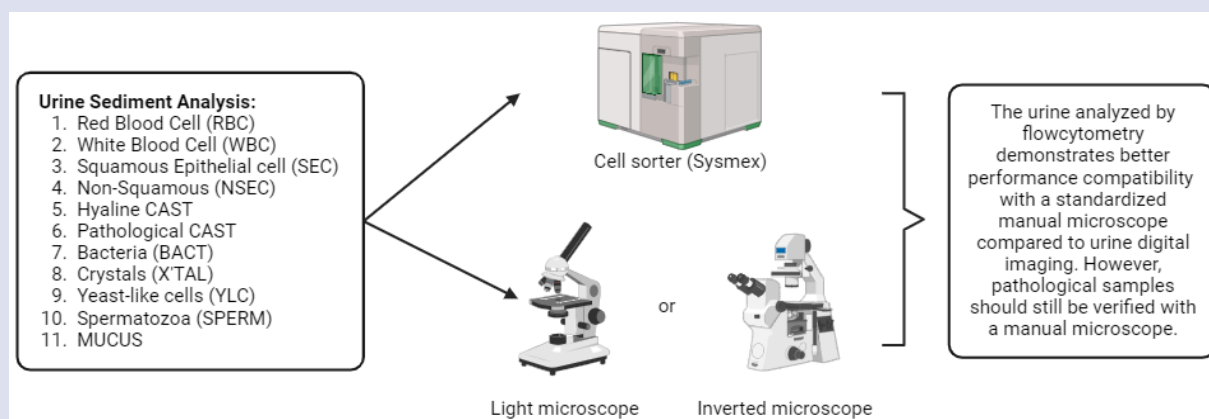
The automatic urine sediment analysis with flowcytometry method revealed better diagnostic work for cast, yeast, and epithelial parameters than the digital imaging method. However, the pathologic samples must still be verified with a manual microscope. Therefore, a more significant amount of samples is needed to give a better picture of the diagnostic performance of both methods.

REFERENCES

1. Enko D, Stelzer I, Böckl M, Derler B, Schnedl WJ, Anderssohn P, et al. Comparison of the diagnostic performance of two automated urine sediment analyzers with manual phase-contrast microscopy. *Clinical Chemistry and Laboratory Medicine (CCLM)* [Internet]. 2020 Jan 28;58(2):268–73. Available from: <https://doi.org/10.1515/cclm-2019-0919>
2. Cho J, Oh KJ, Jeon BC, Lee SG, Kim JH. Comparison of five automated urine sediment analyzers with manual microscopy for accurate identification of urine sediment. *Clinical Chemistry and Laboratory Medicine (CCLM)* [Internet]. 2019 Oct 25;57(11):1744–53. Available from: <https://doi.org/10.1515/cclm-2019-0211>
3. Cavanaugh C, Perazella MA. Urine Sediment Examination in the Diagnosis and Management of Kidney Disease: Core Curriculum 2019. *American Journal of Kidney Diseases* [Internet]. 2019 Feb;73(2):258–72. Available from: <https://doi.org/10.1053/j.ajkd.2018.07.012>
4. Maslachah A, Pramudya D, Pranawa, Widodo, Mardiana N, Tjempakasari A. Inadequate treatment in a patient with minimal change disease (MCD) nephrotic syndrome: a case report. *Bali Medical Journal*. 2023;12(2):2026–9.
5. Wikanningtyas TA, Wahyuni T, Kusumawadi D. The relationship of blood pressure with urine protein examination in fisherman of Batu Karas Village, Cijulang, Pangandaran, West Java. *Bali Medical Journal* [Internet]. 2020 Aug 1;9(2):577–81. Available from: <https://dx.doi.org/10.15562/bmj.v9i2.1887>
6. Rahardjo AR, Wardhani P. Urinalysis Profile of Dengue Viral Infection Patients in Dr. Soetomo General Academic Hospital, Surabaya, from 2019-2021. *JUXTA: Jurnal Ilmiah Mahasiswa Kedokteran Universitas Airlangga* [Internet]. 2023 Aug 10;14(2):94–9. Available from: 10.20473/juxta.V14I22023.94-99
7. Setyorini H, Mardiana N, Tjempakasari A. Risk Factors for Urinary Tract Infection in Hospitalized Patients. *Biomolecular and Health Science Journal* [Internet]. 2019 Jun 30;2(1):4. Available from: <https://doi.org/10.20473/bhsj.v2i1.11549>
8. Brunzel NA. *Fundamentals of Urine and Body Fluid Analysis*. Fourth. Missouri: Elsevier; 2018. 429 p.
9. Tjempakasari A, Yogiantoro M. *Buku Ajar Ilmu Penyakit Dalam*. second. Surabaya: Airlangga University Press; 2015.

10. Nugraha J. Buku Ajar Urinalisis Petunjuk Praktis. 1st ed. Surabaya: Global Persada; 2019.
11. Christy P, Sidjabat HE, Lumban Toruan AA, Moses EJ, Mohd Yusoff N, Puspitasari Y, et al. Comparison of Laboratory Diagnosis of Urinary Tract Infections Based on Leukocyte and Bacterial Parameters Using Standardized Microscopic and Flow Cytometry Methods. *Int J Nephrol* [Internet]. 2022 May 27;2022:1–8. Available from: <https://doi.org/10.1155/2022/9555121>
12. Bottini P, Martinez M, Garlipp C. Urinalysis: Comparison between Microscopic Analysis and a New Automated Microscopy Image-Based Urine Sediment Instrument. *Clin Lab* [Internet]. 2014;60(04/2014). Available from: <https://doi.org/10.7754/clin.lab.2013.130725>
13. Zulkafli Z, Mustaffa R, Yusoff SM. HEMATOPOIETIC PROGENITOR CELLS AS A PREDICTIVE OF CD34+ENUMERATION PRIOR TO PERIPHERAL BLOOD STEM CELLS HARVESTING. *Bali Medical Journal*. 2014;3(3):112–5.
14. İnce FD, Ellidağ HY, Koseoğlu M, Şimşek N, Yalçın H, Zengin MO. The comparison of automated urine analyzers with manual microscopic examination for urinalysis automated urine analyzers and manual urinalysis. *Pract Lab Med* [Internet]. 2016 Aug;5:14–20. Available from: <https://doi.org/10.1016/j.plabm.2016.03.002>
15. Kucukgergin C, Ademoglu E, Omer B, Genc S. Performance of automated urine analyzers using flow cytometric and digital image-based technology in routine urinalysis. *Scand J Clin Lab Invest* [Internet]. 2019 Oct 3;79(7):468–74. Available from: <https://doi.org/10.1080/00365513.2019.1658894>
16. Nakayama A, Tsuburai H, Ebina H, Kino F. Outline and Features of UF-5000, Fully Automated Urine Particle Analyzer. *Sysmex Journal International*. 2018;28(1):1–21.
17. Kawano H. Measurement Technology Used in the Fully Automated Urine Chemistry Analyzer UC-3500. *Sysmex Journal International*. 2019;29(2):56–64.
18. Dirui Industrial. Urinalysis Hybrid (FUS-1000) User Manual. China; 2020.
19. Kouri TT, Gant VA, Fogazzi GB, Hofmann W, Hallander HO, Guder WG. Towards European urinalysis guidelines. *Clinica Chimica Acta* [Internet]. 2000 Jul;297(1–2):305–11. Available from: [https://doi.org/10.1016/s0009-8981\(00\)00256-4](https://doi.org/10.1016/s0009-8981(00)00256-4)
20. Anonymous. S-Y double grid microscopic slide system (leaflet). Taiwan; 2000.
21. Wirawan R, Astrawinata D, Enny. Evaluasi pemeriksaan sedimen urin secara kuantitatif menggunakan sistem Shih-Yung. *Jurnal Berkala Ilmu Kedokteran Universitas Indonesia*. 2004;36:137.
22. Sanderson JB. Phase Contrast Microscopy. In: *Encyclopedia of Life Science*. Wiley-Blackwell; 2002. p. 1–4.
23. Sultana T, Sultana T, Rahman M, Ahmed A. Evaluation of Haematuria and Use of Phase Contrast Microscope: A Short Review. *Journal of Dhaka Medical College* [Internet]. 1970 Jan 1;20(1):63–7. Available from: <http://dx.doi.org/10.3329/jdmc.v20i1.8584>
24. Previtali G, Ravasio R, Seghezzi M, Buoro S, Alessio MG. Performance evaluation of the new fully automated urine particle analyser UF-5000 compared to the reference method of the Fuchs-Rosenthal chamber. *Clinica Chimica Acta* [Internet]. 2017 Sep;472:123–30. Available from: <http://dx.doi.org/10.1016/j.cca.2017.07.028>
25. Bargotyia M, Kumar L, Das P, Kachhap P, Sachdeva V, Monika K. Evaluation of Advantages of Multiple Parameters of an Automated Urine Analyzer in Clinical Practice. *Ann Clin Cytol Pathol*. 2018;4(5):1110.
26. Yüksel H, Kiliç E, Ekinci A, Evliyaoglu O. Comparison of Fully Automated Urine Sediment Analyzers H800-FUS100 and Labumat-Uriised with Manual Microscopy. *J Clin Lab Anal* [Internet]. 2013 Jul;27(4):312–6. Available from: <https://doi.org/10.1002/jcla.21604>
27. Budak YU, Huysal K. Comparison of three automated systems for urine chemistry and sediment analysis in routine laboratory practice. *Clin Lab*. 2011;57(1–2):47–52.
28. Roring ME, Nugraha J, Prasetyo RV, Marpaung FR. The Concordance of Dysmorphic Erythrocyte and Cast Erythrocyte Examination using Flowcytometry, Low Condenser Light Microscope, and Phase Contrast Microscope in Children with Glomerular Hematuria. *Indian Journal of Forensic Medicine & Toxicology*. 2021;15(4):1803–9.
29. Maulidan EB, Marpaung FR. Diagnostic Value of Urinary Dysmorphic Erythrocytes in SLE Patients with Three Different Methods. *INDONESIAN JOURNAL OF CLINICAL PATHOLOGY AND MEDICAL LABORATORY* [Internet]. 2021 Dec 15;28(1):41–5. Available from: <https://doi.org/10.24293/ijcpml.v28i1.1724>
30. Fogazzi GB, Delanghe J. Microscopic examination of urine sediment: Phase contrast versus bright field. *Clinica Chimica Acta* [Internet]. 2018 Dec;487:168–73. Available from: <https://doi.org/10.1016/j.cca.2018.09.036>

GRAPHICAL ABSTRACT



Cite this article: Ritonga NFHM, Marpaung FR, Kahar H, Mardiana N, Puspitasari Y. Performance Comparison of Urine Sediment Analytical Tool by Flowcytometry and Digital Imaging with Standardized Manual Microscopic Testing. *Pharmacogn J*. 2023;12(6): 1189-1196.