

# Anti-Inflammation of Soursop Leaves (*Annona muricata* L.) Against Hemorrhoids in Mice Induced by Croton Oil

Nurul Qurrota Ayun<sup>1</sup>, Kusmardi<sup>2</sup>, Nurhuda<sup>2</sup>, Berna Elya<sup>3,\*</sup>

Nurul Qurrota Ayun<sup>1</sup>, Kusmardi<sup>2</sup>,  
Nurhuda<sup>2</sup>, Berna Elya<sup>3,\*</sup>

<sup>1</sup>Graduate Programme of Herbal Medicine,  
Faculty of Pharmacy, Universitas Indonesia,  
Depok, INDONESIA.

<sup>2</sup>Department of Pathology Anatomy,  
Faculty of Medicine, Universitas Indonesia,  
Jakarta, INDONESIA.

<sup>3</sup>Department of Pharmacognosy-  
Phytochemistry, Faculty of Pharmacy,  
Universitas Indonesia, Depok, INDONESIA.

## Correspondence

Prof. Dr. Berna Elya, M.Si., Apt.

Department of Pharmacognosy-  
Phytochemistry, Faculty of Pharmacy,  
Universitas Indonesia, Depok, 16424, West  
Java, INDONESIA.

Phone no: +62 81314161497

E-mail: berna.elya@gmail.com

## History

- Submission Date: 13-03-2020;
- Review completed: 08-04-2020;
- Accepted Date: 19-05-2020;

DOI : 10.5530/pj.2020.12.112

## Article Available online

<http://www.phcogj.com/v12/i4>

## Copyright

© 2020 Phcogj.Com. This is an open-  
access article distributed under the terms  
of the Creative Commons Attribution 4.0  
International license.

## ABSTRACT

**Background:** Hemorrhoids are rectoanal venous plexus swelling that causes inflammation, pain, and bleeding. Plants with phenolic compounds are known to improve venous tone and anti-inflammation. Soursop leaves (*Annona muricata* L.) known contain phenolic compounds and have been used to cure inflammation. However, studies on anti-inflammatory soursop leaves for hemorrhoids are still limited. **Objective:** This study aims to analyze the effect of Soursop Leaves Ethanol Extract (SLEE) on the histopathological features and expression of COX-2 and TNF $\alpha$  in rectoanal tissue. **Method:** Swiss mice 20 weeks induced 3 times with 6% croton oil through the anus. SLEE doses of 100, 200, and 400 mg/Kg and aspirin as a positive control were given orally for 7 days. Histopathological examination of the rectoanal tissue of mice was assessed by counting cell necrosis, inflammation, vasodilation, and edema using hematoxylin-eosin. Positive cells expressing COX-2 and TNF $\alpha$  were counted on inflammatory epithelial cells using immunohistochemistry. **Results:** Administration of SLEE at all doses showed different levels of inflammation, necrosis, vasodilatation and edema in histopathology of rectoanal tissue P <0.00. All three doses of SLEE show significant anti-inflammatory effects on hemorrhoidal tissue. SLEE doses of 200, 400 mg/Kg significantly decreased COX-2 P <0.05 compared to negative controls, and SLEE doses of 100, 200, and 400 mg/Kg significantly decreased TNF $\alpha$  P <0.05 compared to negative controls. **Conclusions:** SLEE can reduce inflammation and has the potential to be developed as a natural remedy for hemorrhoids.

**Key words:** Hemorrhoid, *Annona muricata*, Croton oil, COX-2, TNF $\alpha$ .

## INTRODUCTION

Hemorrhoids are pathological conditions characterized by swelling of the rectoanal venous plexus which causes inflammation, pain and bleeding in the surrounding tissues.<sup>1</sup> Although not life threatening, hemorrhoids have the potential to reduce quality of life.<sup>2</sup> Riskesdas data (basic health research) in 2015 states that the prevalence of hemorrhoids in Indonesia is estimated at 5.7%, but only 1.5% are diagnosed with a total of 12.5 million people of Indonesia experiencing hemorrhoids.<sup>3</sup>

The exact pathophysiology of hemorrhoids is not yet fully known, the possibility of hemorrhoids can occur due to increased pressure on the rectoanal plexus through various risk factors including a low-fiber diet, sitting for too long, genetic, constipation, chronic diarrhea, obesity, pregnancy, aging and degeneratives.<sup>4</sup> This causes abnormal dilatation and blood vessel distortion which causes secondary complications such as extravasation of blood around the perianal vein and extravasation of fluid into the interstitial space by increased vascular permeability and migration of inflammatory cells (granulocytes and monocytes).<sup>5,31</sup>

Inflammatory tissue can be a potential target for pharmacological treatment of hemorrhoids. Administration of oral anti-inflammatory, suppository, oral creams and plebotonic is known to give good results.<sup>6</sup> Phenolic compounds are known as the most common oral plebotonic agents

used for hemorrhoidal therapy. Phenolic compounds can increase venous tone, reduce capillary permeability, increase lymphatic drainage and have anti-inflammatory effects.<sup>7,32</sup>

*Annona muricata* L. or soursop is one of the plants that has been explored due to its anti-inflammatory and antioxidant effects. The plant parts of *A. muricata* especially leaves have been used as ethnomedicine to treat several diseases including cancer, inflammation, diabetes, liver disease, and abscesses.<sup>8</sup> *A. muricata* contains phytochemicals of acetogenins, alkaloids, megastigmanes and phenolic compounds such as quercetin and gallic acid which are considered to have antioxidant and anti-inflammatory activity.<sup>9</sup> This study aims to determine the activity of Soursop Leaves Ethanol Extract/SLEE (*Annona muricata* L.) which is useful as an anti-inflammatory in hemorrhoids in vivo.

## MATERIALS AND METHODS

### Chemicals and drugs

Croton oil (Sigma), anti COX-2 antibodies (Bioenzy), anti TNF $\alpha$  antibodies (Bioenzy), aspirin, quercetin, gallic acid, and all the other chemicals used in the experiments were of analytical grade from reputed suppliers.

### Preparation of plant extract

Soursop (*Annona muricata* L.) leaves obtained from the Green Zone Herbal garden, Tangerang, Banten

**Cite this article:** Ayun NQ, Kusmardi, Nurhuda, Elya B. Anti-Inflammation of Soursop Leaves (*Annona muricata* L.) Against Hemorrhoids in Mice Induced by Croton Oil. Pharmacogn J. 2020;12(4):784-92.

Province. This plant was determined at the Indonesian Institute of Sciences (LIPI). Soursop leaves extract was made by maceration using 96% ethanol solvent.<sup>27</sup> Soursop leaves dry powder (1 kg) soaked with 10 L of ethanol, stirred in the first 6 hours using a shaker then allowed to stand for 18 hours. The solvent is filtered through (Whatman filter paper No.1) & concentrated with a rotary vacuum evaporator and a water bath until a thick extract is obtained. Then the extract yield is calculated and recorded, and it was kept refrigerated until further use.

### Qualitative & quantitative phytochemical screening

The presence of phytochemical constituents such as flavonoids, tannins, alkaloids, saponins, steroids, terpenes, quinones, total phenols and total flavonoids levels were determined with standardized phytochemical test methods.<sup>10,11</sup>

### Experimental animals

Inbred male Swiss mice ( $\pm 25$  g) aged 20 weeks obtained from the Animal Health Research and Development Laboratory. The study used 24 mice with 6 treatment groups with 4/each. The mice were housed in standard conditions of temperature ( $22 \pm 3^\circ\text{C}$ ), relative humidity ( $55 \pm 5\%$ ), and light (12 h light-dark cycle) before and during the study were included in the experiment. They were fed with standard pellet diet and water *ad libitum*. The experimental protocols approved by health research ethics committee from faculty of medicine Universitas Indonesia for animal research.

### Induction of hemorrhoids

The induction of hemorrhoids was carried out with croton oil with slight modification.<sup>12</sup> 24 mice were randomly distributed in 6 groups; according to the following experimental design in Table 1.

Hemorrhoids were induced to all groups, except the normal control group, by making preparations for croton oil (6% croton oil in acetone). Followed by overnight fasting, then the croton oil was applied with a micropipette into the anus (rectoanal portion, 5mm from the anal opening) as much as 100  $\mu\text{l}$ . The development of edema can be observed after 7 to 8 hours after application of croton oil. Administration of croton oil is done once a day for 3 consecutive days. On the 4<sup>th</sup> day animals from each group were given treatment according to their group for 7 days. On the 11<sup>th</sup> day, all animals were anesthetized using Ketamine-xylazine 75-100 mg/Kg + 5-10 mg/Kg IP and terminated; rectoanal tissue was taken along 10mm to confirm the results of hemorrhoidal treatment through observation of histopathological and immunohistochemical tissue.

### Histopathological analysis

Histopathological examination was carried out on mice anorectal samples fixed in 10% formalin and embedded in paraffin. Sections were cut at 5  $\mu\text{m}$  and stained with H & E (hematoxylin and eosin).<sup>20</sup> The plates were examined under a light microscope (Olympus BX51) and were taken 10 visual fields depicting each piece of anorectal tissue. Histopathological assessment is done by assessing mucosal and submucosal inflammation, necrosis of the lieberkuhn and tunica muscularis, dilatation of blood vessels, edema, and hemorrhage.

Histopathological change analysis was performed by blind reading. The reading is done at 200x magnification. Histopathological readings using Image J. software.

### Immunohistochemical analysis

The COX-2 and TNF $\alpha$  staining procedure was carried out as follows: Tissue samples were fixed with 10% formalin buffered phosphate for 10 hours at 4°C (dehydrated in multilevel ethanol concentration), then paraffin blocks were made, after being passed on xylol, and the tissue was cut with 4  $\mu\text{m}$  thickness for immunohistochemical staining. Next, the preparation was dipped in a 0.01 M citrate buffer (pH 6.0) in the microwave for 5 minutes, followed by dripping 3% hydrogen peroxide for 5 minutes at room temperature. Furthermore, it was incubated with anti COX-2 and TNF $\alpha$  antibodies in phosphate buffer solution (PBS) for 2 hours at room temperature in the humidity chamber. After that, the incubation process is carried out again overnight at 4°C. After the incubation process is complete, the preparation is incubated with the appropriate secondary antibodies for 1 hour at room temperature. The incubation process is continued with HRP-conjugated streptavidin. The protein was visualized using 3,3-diaminobenzidine (DAB) for 10 minutes at room temperature, followed by adding counterstain with Hematoxylin Harris, dehydrating and mounting.

Cells that express each of the above proteins are counted in the rectoanal epithelium using IHC profilers. Furthermore, rectoanal epithelial cells expressing COX-2/TNF $\alpha$  protein was counted from 3 representative fields of vision 400x magnification (carried out by 2 technicians, blind reading). Calculations use the algebraic formula.<sup>13</sup> Calculation method:

IHC Score = (% positive high cell contribution x 4) + (% positive cell contributions x 3) + (% positive low cell contribution x 2) + (% negative cell contributions x 1)

### Statistical analysis

Statistical analysis using 1-way ANOVA test followed by Least Singing Definition (LSD). Data were analyzed using the SPSS 16.

## RESULTS

### Plant extraction

The percent yield of maceration result SLEE was 22.17%. The organoleptic SLEE was dark brown, have a distinctive sweet and chelate taste.

### Phytochemical screening

Phytochemical screening tests on SLEE were the presence of bioactive compounds contained in the extract. The results of the phytochemical screening are seen in Table 2.

### Anti-inflammatory activity of SLEE

#### Body weight observation

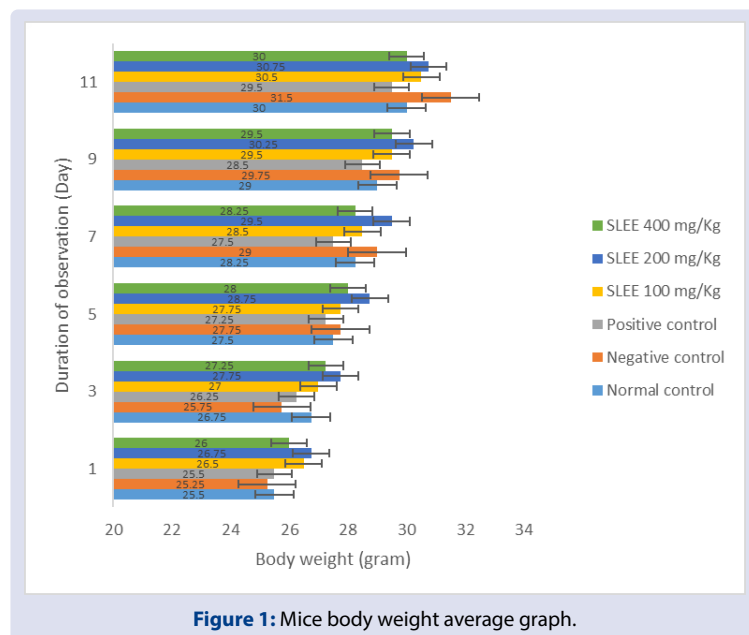
The observations result of body weight of mice in the control group vs. the treatment group can be seen in Figure 1. Weight gain at the end of the observation compared to the base point. There was no significant

**Table 1: Treatment Group.**

No	Groups	Treatment
1	Group I	Acetone p.anal as Normal control
2	Group II	Croton oil 6% p.anal as Negative control
3	Group III	Croton oil 6% p.anal + Aspirin 81 mg/Kg p.o as Positive control
4	Group IV	Croton oil 6% p.anal + SLEE 100 mg/Kg p.o
5	Group V	Croton oil 6% p.anal + SLEE 200 mg/Kg p.o
6	Group VI	Croton oil 6% p.anal + SLEE 400 mg/Kg p.o

**Table 2: Phytochemical screening of SLEE.**

No	Component Bioactive	Tests	Results
1.	Flavonoids	Mg + HCl	+
2.	Tannins	FeCl <sub>3</sub> 3%	+
3.	Alkaloids	TLC	+
4.	Saponins	Foam Test	+
5.	Steroids	Liebermann-Bouchard	+
6.	Terpenes	Liebermann-Bouchard	-
7.	Quinone	NaoH	-
8.	Total Phenolic	Folin Ciocalteu 25% and Na <sub>2</sub> CO <sub>3</sub>	22.85% or 228.5 mgGAE/g extract
9.	Total Flavonoid	AlCl <sub>3</sub>	5.36% or 53.6 mgQE/g extract



**Figure 1: Mice body weight average graph.**

difference between the control vs. treatment group ( $p > 0.05$ ) using the 1-way ANOVA test.

Note: During 11 days of observations the difference in body weight of mice appeared to be an increase in body weight compared to the base point. The mean weight between the normal vs. treatment groups did not show a significant difference ( $P > 0.05$ ) using the 1-way ANOVA test.

### Histopathological observation

Observations of tissue histopathology with hematoxylin-eosin (H&E) staining after croton oil induction and therapy were carried out on several parameters showing hemorrhoidal conditions including inflammation of the mucosa and submucosa, necrosis of the lieberkuhn and tunica muscularis, dilatation of blood vessels, and edema in each treatment group including inflammation of the mucosa and submucosa, necrosis of the lieberkuhn and tunica muscularis, dilatation of the blood vessels, and edema in each treatment group.<sup>28</sup> Histopathological observations of all treatment groups showed that there were significant differences in the improvement of lesion scores. The results of observing lesion scores from 10 visual fields using 200 x magnification can be seen in Figure 2 and Table 3.

### Immunohistochemical observation

The results of COX-2 immunohistochemical staining can be seen in Figure 3. Epithelial cells that positively express COX-2 will look brown, while those that do not express COX-2 will look blue. Based on the results of the Kolmogorof Smirnov normality test it can be said that the

data is normally distributed ( $P > 0.05$ ). The Levene homogeneity test for each group shows homogeneous data ( $P < 0.05$ ). Normally distributed and homogeneous data were continued for the 1-way ANOVA test. Statistical test results showed P value  $< 0.002$  which means that there were significant differences in the COX-2 expression values for each group. Then the LSD test was performed to determine the differences in each group, and the results can be seen in Figure 4.

The results of TNF $\alpha$  immunohistochemical staining can be seen in Figure 5. Epithelial cells that positively express TNF $\alpha$  will appear brown, while those that do not express TNF $\alpha$  will appear blue. Based on the results of the Kolmogorof Smirnov normality test it can be said that the data is normally distributed ( $P > 0.05$ ). The Levene homogeneity test for each group shows homogeneous data ( $P < 0.05$ ). Normally distributed and homogeneous data were continued for the 1-way ANOVA test. Statistical test results showed P value  $< 0.010$  which means that there were significant differences in the TNF $\alpha$  expression values for each group. Then LSD test was performed to determine the differences in each group, and the results can be seen in Figure 6.

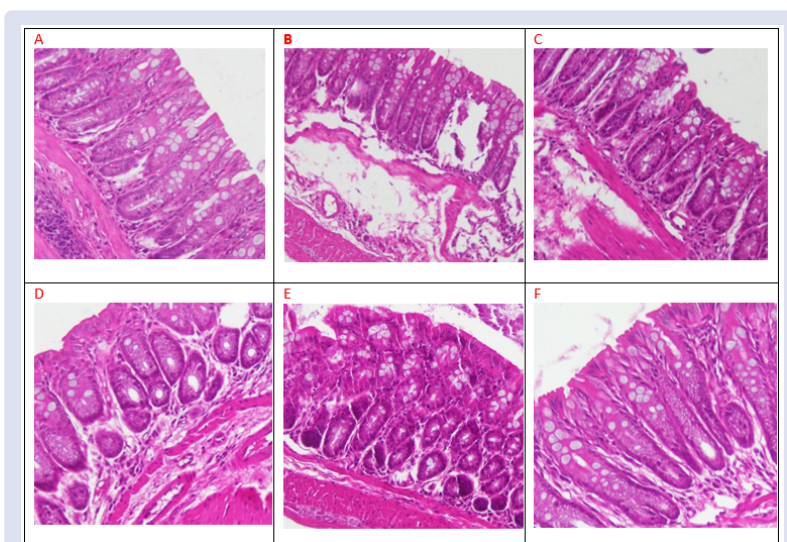
## DISCUSSION

Plants containing phenolic compounds such as flavonoids, tannins, stylbenoids, catechins, lignin and phenolic acids are useful for a large number of inflammatory disorders such as allergies, asthma, autoimmune diseases, inflammatory bowel disease and hemorrhoids.<sup>14</sup> Numerous studies have shown that flavonoids and phenolic compounds have contributed to the antioxidant activity of natural compounds. Besides having antioxidant activity, flavonoids and phenolic compounds

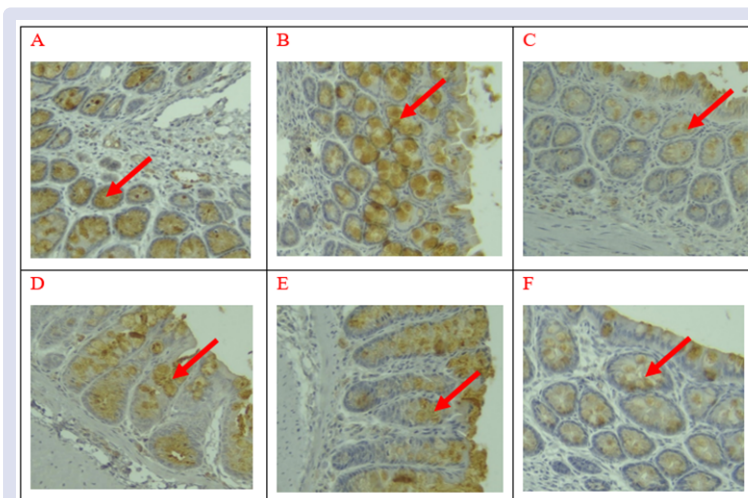
**Table 3: Histopathological evaluation of rectoanal portion of mice.**

Lesions	Treatment group						P Value
	Normal Control	Negative Control	Positive Control	SLEE 100 mg/Kg	SLEE 200 mg/Kg	SLEE 400 mg/Kg	
Inflammation	2.00 ± 0.6	2.60 ± 0.8	2.40 ± 0.8	2.37 ± 0.9	1.97 ± 0.7	1.72 ± 0.8	<0.00
Necrosis	2.00 ± 0.6	2.75 ± 0.7	1.75 ± 0.7	2.25 ± 0.7	1.50 ± 0.6	1.25 ± 0.5	
Vasodilation	2.00 ± 0.8	2.77 ± 0.8	2.27 ± 0.9	2.02 ± 0.9	2.00 ± 0.7	1.90 ± 0.8	
Edema	1.25 ± 0.5	2.25 ± 0.9	2.00 ± 0.9	1.50 ± 0.6	1.50 ± 0.7	1.50 ± 0.6	

Note: Categorical score results are taken based on observations from 10 histo preparatory fields with the value of each category ie, minimal/very small amount of changes >10% = Score 1; Lesions <25% = Score 2; Lesions 25-50% = Score 3; Lesions > 50% = Score 4.

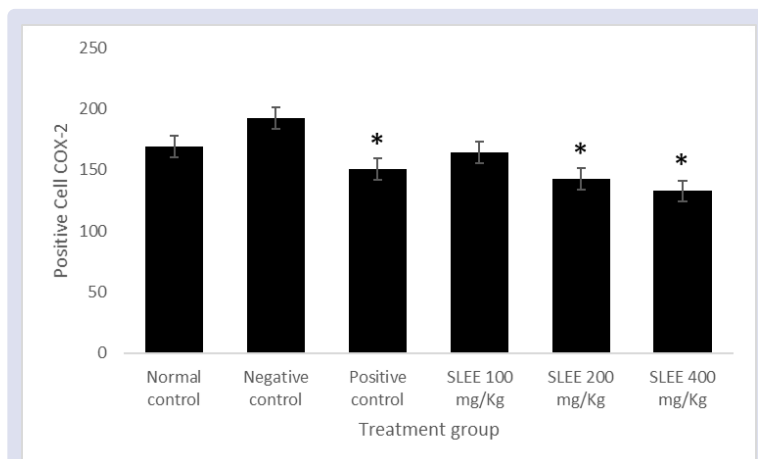


**Figure 2:** Effect of SLEE on histology of rectoanal tissue in a mice model of croton oil-induced hemorrhoids. Recto anal sections of mice: (A) section showing normal histo structure in the normal control group; (B) marked to severe inflammation, congestion, hemorrhage, dilatation of blood vessels, degeneration, and necrosis can be observed in the section of untreated negative control group; (C) section treated with Aspirin as positive control group showing mild inflammation, marked congestion, degeneration, vasodilatation, and necrosis; (D) section treated with SLEE (100 mg/Kg p.o) showing mild inflammation, minimal congestion, dilatation of blood vessels, degeneration, and necrosis (E) sections treated with SLEE (200 mg/Kg p.o) showing minimal inflammation, congestion, dilatation of blood vessels, degeneration, and necrosis; (F) and sections treated with SLEE (400 mg/Kg p.o) showing near normal histo structure (H&E × 200).

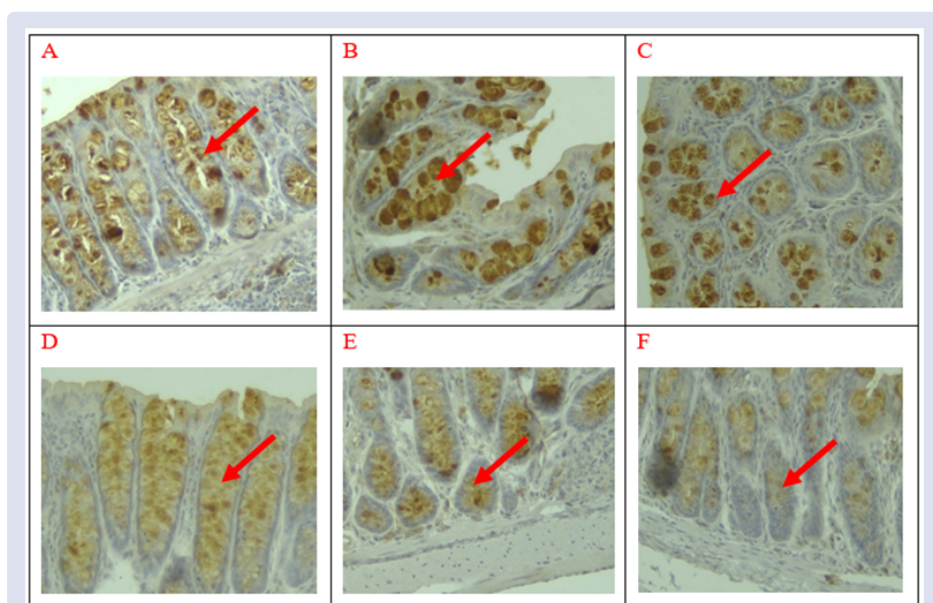


**Figure 3:** Image of tissue tinted immunohistochemistry COX-2 magnification 400 x. Note: Red Arrows indicate positive cells; A: Normal Control, B: Negative Control, C: Positive Control, D: SLEE 100 mg/Kg, E: SLEE 200 mg/Kg, F: SLEE 400 mg/Kg.

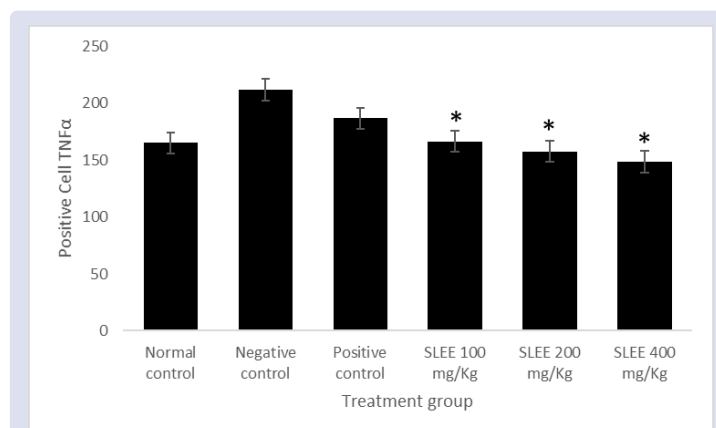




**Figure 4:** Effect of SLEE on COX-2 in mice induced by hemorrhoid. The mean values of all the groups were compared by 1-way ANOVA followed by LSD posttest. \* $P < 0.05$  compared to negative control.



**Figure 5:** Image of tissue tinted immunohistochemistry TNF $\alpha$  magnification 400 x. Note: Red Arrows indicate positive cells; A: Normal Control, B: Negative Control, C: Positive Control, D: SLEE 100 mg/Kg, E: SLEE 200 mg/Kg, F: SLEE 400 mg/Kg.



**Figure 6:** Effect of SLEE on TNF $\alpha$  in mice induced by hemorrhoid. The mean values of all the groups were compared by 1-way ANOVA followed by LSD posttest. \* $P < 0.05$  compared to negative control.

also have an effective role as an anti-inflammatory.<sup>19,30</sup> Phenolic compounds are known as the most common oral plebotonic agents used for hemorrhoidal therapy. Phenolic compounds can increase venous tone, reduce capillary permeability, increase lymphatic drainage and have an anti-inflammatory effect.<sup>7,32</sup>

*Annona muricata* L. or soursop is one of the plants that has been explored due to its anti-inflammatory and antioxidant effects.<sup>29</sup> The plant parts of *A. muricata* especially leaves have been used as ethnomedicine to treat several diseases including cancer, inflammation, diabetes, liver disease, and abscesses.<sup>8</sup> *A. muricata* contains phytochemical acetogenins, alkaloids, megastigmanes and phenolic compounds such as quercetin and gallic acid which are considered to have antioxidant and anti-inflammatory activity.<sup>9</sup>

In this study we tried to investigate the anti-inflammatory potential of soursop leaves extract against hemorrhoid in mice induced with croton oil. Topical application of croton oil can induce an inflammatory response to the skin, followed by severe vasodilation and infiltration of cells occurring at the peak of edema, neutrophil and macrophage activity reaching a maximum within six hours. The phorbol ester content in croton oil, such as tetradecanoylphorbol acetate (TPA) will increase vascular permeability, inducing arachidonic acid metabolite synthesis and expression of COX-2, IL-1 $\beta$ , TNF $\alpha$  and ICAM-1 adhesion molecules.<sup>16</sup>

This is similar to the mechanism of hemorrhoids in humans. Weakening of tone and structure of veins, as well as injury during defecation cause congestion and hypoxia in the tissues. Endothelium cells induce a series of cellular modification, increase the concentration of cytosolic calcium and prostaglandin inflammatory mediators of phospholipase A2 (PLA2) initiated by the enzyme cyclooxygenase-2 (COX-2). Leukocytes and mast cells release pro-inflammatory cytokines tumor necrosis factor-TN (TNF- $\alpha$ ), interleukin-1 $\beta$  (IL-1 $\beta$ ), IL-6, and chemokines (CXC 4 chemokine receptors) which will produce an oxidative stress environment. Neutrophils also release histamine, serotonin, and lysosomal enzymes (elastase, collagenase) thereby increasing capillary permeability, and fragility of blood vessel walls.<sup>17</sup>

In this study, to prove the anti-inflammatory potential of SLEE in hemorrhoids is evidenced by histopathological assessment of inflammatory cells, necrosis, vasodilation and edema. Inflammation plays an important role in the mechanism of increasing capillary permeability and developing the pathophysiology of hemorrhoids.<sup>7</sup> The inflammatory process makes the arterioles of the lamina propria nodules prone to erosion during bowel movements with the resulting bleeding. The combination of sinusoidal constriction and chronic inflammatory processes in the nodules results in stagnation of blood in the sinusoids.<sup>21</sup> Stagnation causes locally controlled hypercoagulability, which increases clot formation and ultimately results in thrombosis. Thrombosis can cause ischemia, ulceration and nodular surface necrosis.<sup>22,23</sup>

Hemorrhoids are digestive disorders characterized by enlarged rectal venous plexus and anal canal which can cause pain, bleeding, itching and inflammation.<sup>1</sup> Internal hemorrhoid are covered with columnar mucosa, causing mucous deposition on the perianal skin, which can also cause itching and irritation of the perineum. Prolapse tissue can also inhibit the ability of the anal threshold to close so that faecal stool can come out.<sup>24</sup> Pain in hemorrhoids usually originates from external hemorrhoids which have extensive thrombosis with edema and inflammation.<sup>25</sup> Based on our observations in this study, from all SLEE treatments for hemorrhoids gave significant results to the repair of the histo rectoanal structure of the mice ( $P < 0.00$ ).

We also observe the potential of SLEE as an anti-inflammatory using immunohistochemistry in the rectoanal tissue of mice. SLEE also

showed a strong anti-inflammatory potential by significantly reducing COX-2 and TNF $\alpha$  expression compared with negative controls at doses of 200 and 400 mg/Kg ( $P < 0.05$ ). *Annona muricata* is known to contain gallic acid polyphenols which have many beneficial effects including antioxidant, anti-inflammatory, antidiabetic and anti-carcinogenic properties.<sup>26</sup> The anti-colitis effect of gallic acid in BALB/c mice with DSS-induced colitis suggests that gallic acid has the potential to suppress pro-inflammatory cytokines (TNF $\alpha$ , IL-1 $\beta$ , IL-17 and IFN- $\gamma$ ) and inflammatory mediators, such as iNOS and COX-2. Furthermore, the mechanism of gallic acid is known to inhibit the activation and translocation of p65-NF- $\kappa$ B, and the IL-6 / STAT3 pathway.<sup>15</sup>

Others *in vitro* studies of *A. muricata* leaf extract showed anti-inflammatory activity by inhibiting inflammatory mediators, TNF $\alpha$ , IL-1 $\beta$ , IL-6 and nitric oxide (NO). The administration of *A. muricata* leaves extract showed a significant inhibition of TNF $\alpha$  of 46.8% *in vitro* on LAW-induced RAW264.7 cells. Administration of *A. muricata* leaves extract at a dose of 50  $\mu$ g/mL in RAW264.7 cells resulted in TNF $\alpha$  levels of 264.69 pg/mL which were found to be equivalent to normal cells. *A. muricata* leaves extract also significantly inhibited IL-6 and NO levels with a dose concentration of 50 and 75  $\mu$ g/mL resulting in inhibition of 63.89% (219.13 pg/mL) and 70.67% (9.79  $\mu$ M).<sup>18,21</sup> Anti-nociceptive/anti-inflammatory mechanisms are also studied through inhibition of cyclooxygenase (COX), lipoxygenases (LOX) and other inflammatory mediators by flavonoids in *A. muricata*.<sup>33</sup>

## CONCLUSION

Based on research conducted, it can be concluded that the Soursop Leaves Ethanol Extract (SLEE) (*Annona muricata* L.) can be used to cure hemorrhoid.

## ACKNOWLEDGEMENT

This study is supported by the PITTA 2019 Grant from the Directorate of Research and Humanitarian Involvement (DRPM), Universitas Indonesia.

## CONFLICTS OF INTEREST


The authors declare no conflicts of interest.

## REFERENCES

- Rahimi, R., & Abdollahi, M. Evidence Based Review of Medicinal Plants Used for the Treatment of Hemorrhoids. *International Journal of Pharmacology*. 2013; 9 (1): 1-11.
- Septadina, I. S., & Veronica, F. Gambaran Histopatologi Epitel Transitional Kolorektal pada Pasien Hemoroid. *Jurnal Kedokteran dan Kesehatan*. 2015; 2(1), 85-91.
- Badan Penelitian dan Pengembangan Kesehatan. Riset Kesehatan Dasar. Jakarta: Kementerian Kesehatan Republik Indonesia. 2015.
- Qureshi, W. Hemorrhoid Disease and the Role of the Gastroenterologist. *Gastroenterology & Endoscopy News*. 2018; 1-4.
- Kaidar-person, O., Person, B., Wexner, S. D., & Ed, F. Hemorrhoidal Disease: A Comprehensive Review. *J Jamcoll Surgery*. 2007; 102-117.
- Lohsiriwat, V. Approach to Hemorrhoids. *Current Gastroenterology Reports*. 2013; 15(7), 332.
- Lohsiriwat, V. Treatment of hemorrhoids: A coloproctologist's view. *World Journal of Gastroenterology*. 2015; 21(31), 9245-9252.
- Mariam, S., Jantan, I., Haque, A., & Arshad, L. Exploring the Leaves of *Annona muricata* L. as a Source of Potential Anti-inflammatory and Anticancer Agents. *Frontiers in Pharmacology*. 2018; 9(6), 1-20.
- Coria-Téllez, A. V., Montalvo-González, E., Yahia, E. M., & Obledo-Vázquez, E. N. *Annona muricata*: A comprehensive review on its traditional medicinal uses, phytochemicals, pharmacological activities, mechanisms of action and toxicity. *Arabian Journal of Chemistry*. 2018; 11(5), 662-691.
- Departemen Kesehatan RI. Parameter Standar Umum Ekstrak Tumbuhan Obat. Jakarta: Departemen Kesehatan RI. 2000; 32-38.
- Kemenkes. Suplemen III Farmakope Herbal Indonesia Edisi I. Jakarta: Kementerian Kesehatan Republik Indonesia. 2013.

12. Azeemuddin, M., Viswanatha, G. L., Rafiq, M., Thippeswamy, A. H., Baig, M. R., Kavya, K. J., Shyam, R. An Improved Experimental Model of Hemorrhoids in Rats: Evaluation of Antihemorrhoidal Activity of an Herbal Formulation. *ISRN Pharmacology*. 2014; 1–7.
13. Varghese, F., Bukhari, A. B., Malhotra, R., & De, A. IHC Profiler: An Open Source Plugin for the Quantitative Evaluation and Automated Scoring of Immunohistochemistry Images of Human Tissue Samples. *Plos One*. 2014; 9(5): 1-11.
14. Aziz, Z., Kit, W., Danish, M., Hisham, B., Ling, W., & Yaacob, S. Efficacy and tolerability of micronized purified flavonoid fractions (MPFF) for haemorrhoids: A systematic review and meta-analysis. *Complementary Therapies in Medicine*. 2018; 39, 49–55.
15. Kumar, A., Mohebbali, N., Mohd, N., & Yeng, C. Gallic acid suppresses inflammation in dextran sodium sulfate-induced colitis in mice: Possible mechanisms. *International Immunopharmacology*. 2015; 1-10.
16. Favacho, H. A. S., Oliveira, B. R., Santos, K. C., Medeiros, B. J. L., Sousa, P. J. C., Perazzo, F. F., & Carvalho, J. C. T. Anti-inflammatory and antinociceptive activities of *Euterpe oleracea* oil. *Brazilian Journal of Pharmacognosy*. 2011; 21(1), 105–114.
17. Dudek-Makuch, M., & Studzińska-Sroka, E. Horse Chestnut - Efficacy and safety in chronic venous insufficiency: An overview. *Brazilian Journal of Pharmacognosy*. 2015; 25(5), 533–541.
18. Gavamukulya, Y., Wamunyokoli, F., & El-Shemy, H. A. *Annona muricata*: Is the natural therapy to most disease conditions including cancer growing in our backyard? A systematic review of its research history and future prospects. *Asian Pacific Journal of Tropical Medicine*. 2017; 10(9), 835–848.
19. Andersen, O. M., & Markham, K. R. *Flavonoids: Chemistry, Biochemistry and Applications* (9th Edition). Boca Raton, USA: CRC Press. 2006.
20. Fischer, A. H., Jacobson, K. A., Rose, J., & Zeller, R. Hematoxylin and Eosin Staining of Tissue and Cell Sections. *Cold Spring Harbor Protocols*. 2008; 3(5), 1-2.
21. Morgado, P.J., Suarez, J.A., Gomez, L.G. Histoclinical basic for a new classification of hemorrhoidal disease. *Dis Colon Rectum*. 1988; 31, 474-480.
22. Margetis, Nikolaos. Pathophysiology of Internal Hemorrhoids. *Annals of Gastroenterology*. 2019; 32 (3), 264-272.
23. Rock, Kenneth The inflammatory response to cell death. *Annual Review of Pathology*. 2008; 3: 99–126.
24. Ganz, R. A. The evaluation and treatment of hemorrhoids: A guide for the gastroenterologist. *Clinical Gastroenterology and Hepatology*. 2013; 11(6), 593–603.
25. Sjamsuhidajat, R., Karnadihardja, W., Prasetyono, T., Rudiman, R. *Buku Ajar Ilmu Bedah*, Ed.3. Jakarta: Penerbit Buku Kedokteran EGC. 2002.
26. George, V. C., Kumar, D. R. N., & Suresh, P. K. Antioxidant, DNA protective efficacy and HPLC analysis of *Annona muricata* (soursop) extracts. *J Food Scientists & Technologists*. 2015; 52(4), 2328–2335.
27. Indrawati, L., Ascobat, P., Bela, B., Abdullah, M., Surono, I. S. The effect of *Annona muricata* leaf extract on nutrition status and cytotoxicity in colorectal cancer. *Asia Pacific Journal Clinical Nutrition*. 2017; 26(4), 606-612.
28. Morgado, P.J., Suarez, J.A., Gomez, L.G. Histoclinical basic for a new classification of hemorrhoidal disease. *Dis Colon Rectum*. 1988; 31, 474-480.
29. Evans, W.C. *Pharmacognosy* 16th edition (16th ed.). New York, USA: Saunders Elsevier. 2009.
30. Sundang, M., Nasir, S., Sipaut, C., & Othman, H. Antioxidant activity, phenolic, flavonoid, and tannin content of Piper betle and *Leucosyke capitella*. *Malaysian Journal of Fundamental & Applied Sciences*. 2012; 8(1), 1–6.
31. Suprijono, M. A. HEMORRHOID. *SULTAN AGUNG*, XLIV (118), 23–38. 2009.
32. Supriyatna, Febriyanti, R.M., Dewanto, Wijaya, I., Ferdiansyah, F. *Fitoterapi Sistem Organ, Pandangan Dunia Barat Terhadap Obat Herbal Global*, Ed.1. Yogyakarta: Deepublish. 2014.
33. Wahab, S. M. A., Jantan, I., Haque, M. A., & Arshad, L. Exploring the leaves of *Annona muricata* L. as a source of potential anti-inflammatory and anticancer agents. *Frontiers in Pharmacology*. 2018; 9(JUN), 1–20.

## GRAPHICAL ABSTRACT



## SUMMARY

- Hemorrhoids are rectoanal venous plexus swelling that causes inflammation, pain, and bleeding. Soursop leaves (*Annona muricata* L.) known contain phenolic compounds and have been used to cure inflammation.
- Soursop leaves ethanol extract/SLEE (*Annona muricata* L.) contains flavonoids, tannins, alkaloids, saponins, steroids, and phenolic compounds with total phenol levels of 22.85% or 228.5 mgGAE/g extract, total flavonoid levels of 5.36% or 53.6 mgQE/g extract.
- Soursop leaves ethanol extract/SLEE (*Annona muricata* L.) had a significant improvement in lesions  $P < 0.00$  to the parameters of necrosis, inflammation, vasodilation and edema assessed by the histopathological severity score of the tissue with H&E staining.
- Soursop leaves ethanol extract/SLEE (*Annona muricata* L.) has anti-inflammatory activity assessed by suppressing COX-2 and TNF $\alpha$  expression. SLEE doses of 200, 400 mg/Kg significantly decreased COX-2  $P < 0.05$  compared to negative controls, and SLEE doses of 100, 200, and 400 mg/Kg significantly decreased TNF $\alpha$   $P < 0.05$  compared to negative controls.

## ABOUT AUTHORS



### Prof. Dr. Berna Elya, M.Si., Apt.

Professor and Head of Phytochemistry and Pharmacognosy, Faculty of Pharmacy, Universitas Indonesia (UI) Depok, West Java, Indonesia. She is expert in the area of Pharmacognosy and Phytochemistry, working in drug discovery of herbal plants, extraction technology, structure elucidation, and degenerative disease such as diabetes mellitus, antyhypertension, and cholesterol.





**Dr. Drs. Kusmardi, M.Sc.**

Senior Lecturer and Researcher at Anatomic Pathology, Faculty of Medicine, Universitas Indonesia. The major research focus on colorectal and breast cancer, include the potential inhibition of some Indonesian natural medicine on the both carcinogenesis, the identification of normal tissue vs cancer development using some molecular marker and computational model. He wrote the mouse model for breast cancer book, the mouse model for colorectal adjuvant chemopreventive book and Lunasin: a soybean polypeptide as chemopreventive adjuvant for colon cancer. His Research Areas are Immunology, Pathobiology, Cancer Biology, Herbal Medicine, Biomedical Sciences, Oncology, Animal Model for Cancer Research, Biostatistics and Research Methodology, computational molecular medicine.



**Dr. Nurhuda Sahar, MS.**

Senior Lecturer and Researcher at Laboratorium Reproduction, Faculty of Medicine, Universitas Indonesia. The major research focus on Biology Reproduction, include the Increased Progesterone on the Day of Administration of hCG in Controlled Ovarian Hyperstimulation Affects the Expression of HOXA10 in Primates' Endometrial Receptivity, the LIF and LIF-R Protein Expression in *Macaca nemestrina* Midluteal Endometrial Tissues After Controlled Ovarium Stimulation, the Endometrial  $\alpha\beta3$  Integrin Expression in *Macaca nemestrina* Endometrium after Gonadotrophin Administration for Controlled Ovarian Hyperstimulation.



**Nurul Qurrota Ayun, S.Farm., Apt.**

Master Student at Herbal Medicine, Faculty of Pharmacy, Universitas Indonesia, Depok, West Java, Indonesia.

The master research focus on natural medicine development as anti-inflammation of soursop leaves (*Annona muricata* L.) against hemorrhoids in mice induced by croton oil.

**Cite this article:** Ayun NQ, Kusmardi, Nurhuda, Elya B. Anti-Inflammation of Soursop Leaves (*Annona muricata* L.) Against Hemorrhoids in Mice Induced by Croton Oil. *Pharmacogn J.* 2020;12(4):784-92.