

# Effectiveness of Sidr Honey on the prevention of ethanol-induced gastrulcerogenesis: role of antioxidant and antiapoptotic mechanism

Manal Mohamed Elhassan Taha<sup>1\*</sup>, Siddig Ibrahim Abdelwahab<sup>1</sup>, Rashad Elsanousi<sup>1</sup>, Bassem Y. Sheikh<sup>2</sup>, Mahmood Ameen Abdulla<sup>3</sup>, Saif Eldeen Babiker<sup>1</sup>, Husham Elraih<sup>1</sup>, Eldaw Mohamed<sup>1</sup>

<sup>1</sup> Department of Biomedical Research Unit, Medical Research Centre, Jazan University, Jazan, Saudi Arabia

<sup>2</sup> MABL Scientific Chair, Department of Surgery, College of Medicine, Taibah University, Saudi Arabia

<sup>3</sup> Department of Molecular Medicine, Faculty of Medicine, University of Malaya, Malaysia.

## ABSTRACT

**Background:** Sider (*Ziziphus spina-christi* (L.) Desf.) Honey has been used for the treatment of gastrointestinal disorders including peptic ulcer. **Aim of the study:** The mechanism of the antiulcer effect of sider honey was studied placing emphasis on its role to block oxidative damage and apoptosis during ethanol-induced gastric ulceration in rats. The mechanism of the antiulcer effect of sider honey was studied placing emphasis on its role to block oxidative damage and apoptosis during ethanol-induced gastric ulceration in rats. **Materials and methods:** Experimental animals were orally treated with sidr honey (100, 250 and 500 mg/kg, respectively) or omeprazole and subsequently exposed to 95% ethanol (5 mL/Kg, orally) to induce acute gastrulcerogenesis. Effectiveness of sidr honey was evaluated using ulcer index, pH of gastric juice, mucus content, morphological analyses, glutathione assay and malondialdehyde level. The anti-apoptotic role of sidr honey was studied using immunohistochemical staining of gastric tissues using monoclonal antibodies of Bax pathway. **Results:** Dose-response studies in ethanol-induced ulcer indicate that sidr honey significantly blocks gastric lesions at lower dose (100 mg/kg). Lipid peroxidation and glutathione depletion were significantly inhibited by sidr honey. Sidr honey modulated the immuno-expression of mitochondrial associated protein (Bax). **Conclusion:** Thus, sider honey plays a considerable role in gastro protection by acting as a potent antioxidant and antiapoptotic agent. Future study is required to explore its potential clinical usage.

**Key words:** Antiapoptotic Mechanism, Antioxidant Agents, Gastro protection, Monofloral Nectar, Sidr Honey.

## INTRODUCTION

The ethno-medicinal and ethno-nutritional uses of honey have been historically known.<sup>1,2</sup> Modern biomedical research has demonstrated that honey is a considerable natural antioxidant and has potential remedial value in the treatment of tumors, diseases of heart and eye, and inflammation.<sup>3</sup> The curative potential of honey involves free-radical scavenging activities and antibacterial

properties, as well as wound-healing and anti-inflammatory activities.<sup>3,4</sup> Previous phytochemical reports on honey showed that this natural sweetener contains not less than one hundred phyto-substances. Potential pharmacologically active ingredients of honey include phenolic compounds, flavonoids and other phytochemicals which display a broad range of biological activities.<sup>4,6</sup> Actual health benefits derived from honey depend on the quality and purity of this natural substance.<sup>7</sup> Monofloral honey is a type of honey which has a high value in the marketplace because it has a distinctive flavor or other attribute due to its being predominantly from the nectar of one plant species.<sup>8</sup> Sidr monofloral honey is found in the desert areas of Yemen, Saudi Arabia and Pakistan's Potohar region.<sup>9</sup> Yemeni sidr honey is considered as the finest and of the best quality all

### \*Corresponding author:

Dr. Manal Mohamed Elhassan Taha

Department of Biomedical Research Unit,

Medical Research Centre,

Jazan University, Jazan, Saudi Arabia.

E-mail: manalroa@yahoo.com

DOI: 10.5530/pj.2015.3.3

around the world and that is because of the Yemen's climate and environment are good habitats for making honey.<sup>6</sup>

Honey is traditionally used to treat dyspepsia and peptic ulcers.<sup>2,10</sup> *Helicobacter pylori*, the pathogenic agent in numerous conditions of digestive disorders and gastric ulcer was found to be susceptible to honey.<sup>11</sup> Also, honey is effective in treating bacterial gastroenteritis.<sup>3,12</sup> There are no scientific reports on the effectiveness of sidr monofloral honey to validate its traditional use on the cure and prevention of peptic ulcer. Many animal models of gastrulcerogenesis are used such as ethanol- or pylorus ligation-induced gastric ulcer.<sup>13,14</sup> Therefore, the current study was designed to investigate the effectiveness of sidr monofloral honey (SH) against ethanol-induced gastric ulcerogenesis.

## MATERIALS AND METHODS

### Materials

Pure sidr (*Ziziphus spina-christi* (L.) Desf.) honey was obtained from an exclusive honey shop in Jazan, Saudi Arabia.

### Animals husbandry and caging

Sprague Dawley male rats (220 ± 20g) were obtained from the Experimental Animal House, Medical Research Centre, Jazan University, Jazan, Saudi Arabia. Animals were divided randomly into six groups (n=5). Food and water were provided throughout the experiment *ad libitum*. All animals received human care according to the criteria outlined in the "Guide for the Care and use of Laboratory Animals" prepared by the Medical Research Centre, Jazan University, Jazan, Saudi Arabia. Ethical approval was obtained in June 2012 [Ethic No MRC/2012/BMRU/132].

### Ethanol-induced gastric ulcer

Rats were fasted for 48h prior to oral dosing. One hour before intragastric administration of 95% ethanol (5 ml/kg) animal treated as follow: group I treated with vehicle (5% Tween 80, v/v, 5 ml/kg.B.W.), group II omeprazole (20 mg/kg), group (III, IV & V) with honey (100, 250 and 500 mg/kg, respectively). One h after ethanol dosing, all animals were sacrificed under anesthesia (ketamine & xylazine) and their blood was collected.<sup>15</sup> Experimental design is depicted in Table 1.

### Mucus content and pH of Gastric juice

Gastric juice of each animal was collected and centrifuged to measure the pH (meq/l) from the supernatant using the pH-meter. Weight of the gastric mucosa from the sedimentation using precise balance was obtained.<sup>16</sup>

### Gross assessment of ulcer

Gastric ulcer appears as elongated bands of hemorrhagic lesions. The length (mm) and the width (mm) of each bands were measured using planimeter [(10×10 mm<sup>2</sup>=ulcer area) under stereomicroscope (1.8×)]. The area of each ulcer lesion was measured by counting the number of small squares (2×2) mm covering the length and width of each ulcer band. The sum of the areas of all lesions for each stomach was applied in the calculation of the ulcer area (UA) wherein the sum of small squares (4×1.8 = UA mm<sup>2</sup>). The inhibition percentage (I %) was calculated by the following formula described in<sup>17</sup> with slight modifications:

#### Inhibition

$$\text{percentage (I \%)} = \frac{[(UA_{\text{control}} - UA_{\text{treated}})]}{UA_{\text{control}}} \times 100\%$$

**Table 1: Effect of Sidr honey on ulcer index, gastric acidity and mucus weight of ethanol induced gastric ulcer**

Animal group	pretreatment (5ml/kg)	pH of Gastric tissue	Mucus weight (g)	Ulcer Area (mm <sup>2</sup> ) (mean±S.E.M)	% Inhibition
I	Ulcer control	3.61±0.15	0.99±0.04	482.4±40.89	-
II	Omeprazole (20 mg/kg)	7.0±1.14	0.90±0.07	108±9.60	77.59
III	Sidr Honey (100 mg/kg)	4.2±0.31	1.10±0.13	104±3.50	78.42
IV	Sidr Honey (250 mg/kg)	4.9±0.02	1.37±0.02	69±1.52	85.69
V	Sidr Honey (500 mg/kg)	6.5±0.01	1.41±0.01	36±5.36	92.53
VI	Normal control	5.06±0.09	0.258±0.06	-	-

Values are presented as mean ± SEM of five rats in each group. Groups with different alphabets are statistically different.

### Microscopic evaluation using hematoxylin and eosin

For histopathological evaluation, a small fragment of each animal gastric ulcer was fixed with 10% buffered formalin solution. Formalin fixed and paraffin embedded (FFPE) sections of 4  $\mu\text{m}$  were stained with hematoxylin and eosin (H &E) for light microscopy assessment.<sup>18</sup>

### Immunohistochemistry

The FFPEs were cut to 4  $\mu\text{m}$  thickness (Leica Rotation Microtome, Wetzlar, Germany). The tissue sections were then mounted on 3-aminopropyltrimethoxysilane (APES)-treated glass slides, dried overnight at ambient temperature and stored at  $-4^{\circ}\text{C}$  until used for immunohistochemistry. Deparaffinized FFPE gastric sections in buffer solutions were boiled in a microwave oven to retrieve the antigen. Endogenous peroxidase was blocked with 3% (v/v)  $\text{H}_2\text{O}_2$ . After washing with Tris-buffered saline (pH 7.6) (TBS) containing 0.1% Tween-20, the sections were blocked with 0.01% d-biotin for pre-treatment with the heat-induced epitope retrieval method. The sections were further blocked with 3% bovine serum albumin for 1 h to minimise nonspecific antibody binding and then incubated with appropriate dilution of primary antibodies for 1 h at room temperature or overnight ( $\sim 18$  h) at  $4^{\circ}\text{C}$ . The control sections were not incubated with primary antibody. Immunostaining was performed using LSAB<sup>®</sup>2 System-HRP kit (DAKO, Carpinteria, USA) at room temperature according to manufacturer's instructions. The slides were treated with a biotin-conjugated secondary antibody for 30 min followed by 30 min incubation with peroxidase-conjugated streptavidin at room temperature. At each step, the slides were washed with TBS. Peroxidase activities were detected after incubating the samples with 3, 3'-diaminobenzidine (DAB) by the appearance of a brown precipitate that is insoluble in alcohol. Finally, the sections were counterstained with hematoxylin. Specificity of staining was controlled by omission of primary antibody.

### Immunohistochemical staining of Bax

Monoclonal anti-rat Bax antibodies (Santa Cruz Biotech., USA) were used at dilution of 1:200. The sections were pre-treated by boiling in 10 mM Tris buffer containing 1 mM EDTA (pH 6.0) for 30 min to unmask the antigen. The sections were then incubated with the primary antibody for 70 min at room temperature.

### Phytochemical analysis

#### *Total Phenolic (TPC) and Flavonoid (TFC) Content*

The Folin-Ciocalteu method was utilized to examine the total phenolic content (TPC) of the honey. Values of TPC were estimated by comparing the absorbance of each sample with a standard response curve generated using gallic acid. The total flavonoid content was determined by using a colorimetric assay of aluminum tetrachloride as previously described. A calibration curve was calculated with quercetin, and the results were expressed as mg quercetin equivalents (CE)/100 g of honey.

#### *Qualitative phytochemical screening*

Sidr honey was subjected to phytochemical test using standard method.<sup>19</sup> Nuclear magnetic resonance (NMR) analysis was used to confirm the functional chemical groups in the honey.

### Statistical analysis

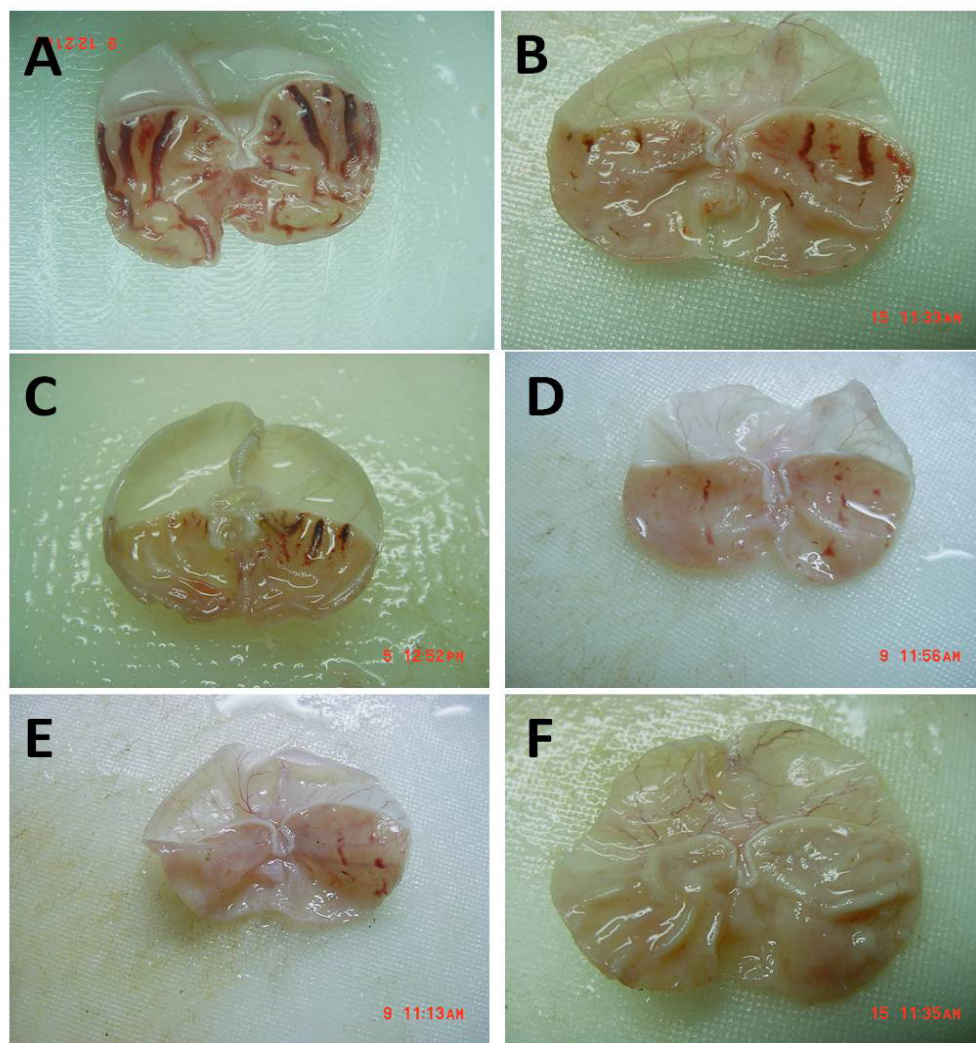
All values were reported as mean  $\pm$  S.E.M. Statistical significant differences between groups were assessed using one-way ANOVA followed by Tukey's *post hoc* multiple comparison test. A value of  $P < 0.05$  or lower was considered as a significant difference.

## RESULTS AND DISCUSSION

Peptic ulcer is known to be one of the most common disturbing ailments. The utilization of herbal medicine and natural substances for the prevention and cure of human diseases is persistently and globally moving ahead. Phenolic compounds constitute the largest group of plants secondary metabolites and have attracted special attention due to their health-promoting characteristics.<sup>20,21</sup> Therefore, the current paper was an attempt to investigate the anti-ulcerogenic mechanism(s) of sider honey on ethanol-induced ulcer in rats. The model used in this study is oxidative stress-based mechanism.

Honey is a supersaturated liquid substance of sugars, mainly composed of glucose and fructose, containing also some nutrients such minerals, proteins, amino acids, enzymes, vitamins and polyphenols. Among polyphenols, flavonoids are the most plentiful and are directly related to its therapeutic properties. Honey certainly influences risk factors for heart diseases by inhibiting inflammation,





**Figure 1:** Gross evaluation of gastric wall from various animal groups.

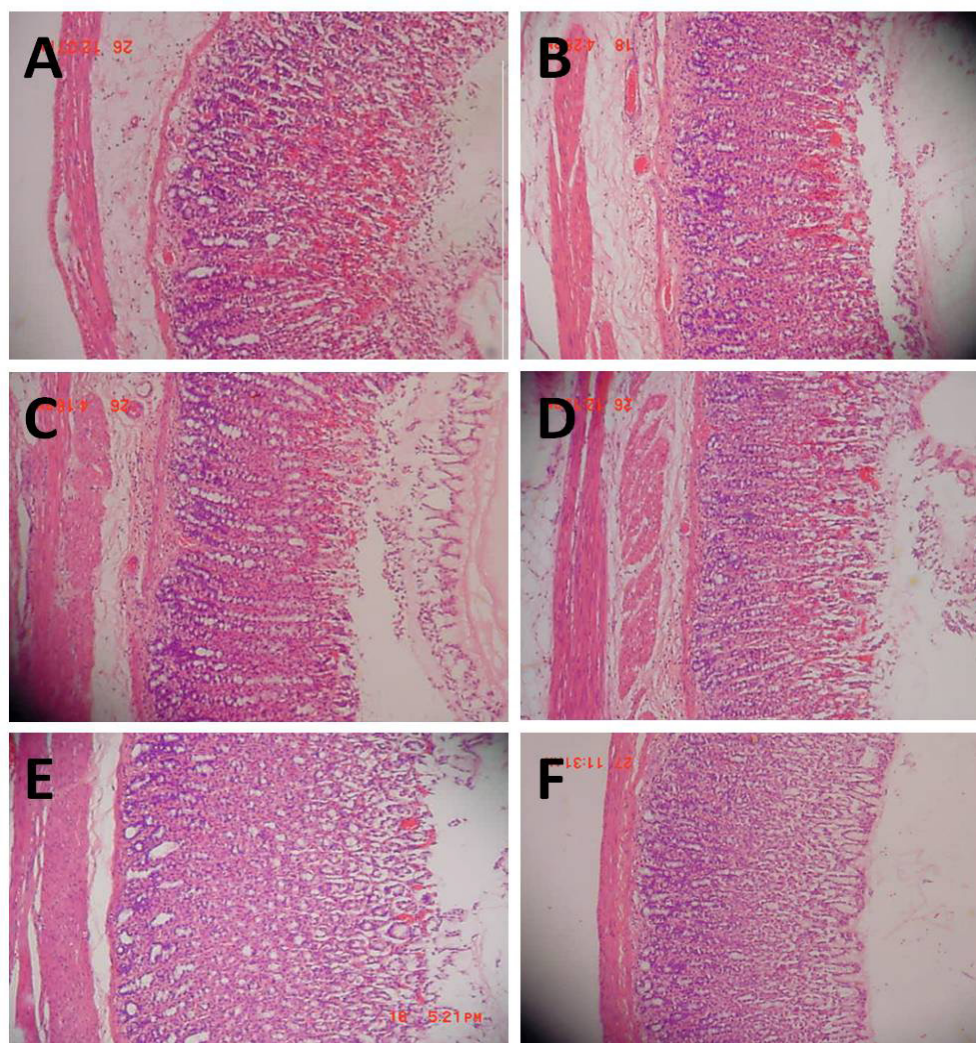
Results showed that rats pre-treated with sidr honey at doses of 100, 250 & 500 mg/kg kg (photo 1C, 1D & 1E, respectively) and omeprazole (20 mg/kg, photo 1B) had considerably reduced areas of gastric ulcer formation compared to rats pre-treated with only vehicle (ulcer control group, Figure 1A) (Magnification: 1.8 X).

enhancing endothelial function, as well as the lipid profile, and increasing low-density lipoprotein resistance to oxidation. The evidence of the bioactivities of honey can be credited to its polyphenolic contents which, in turn, are regularly linked to its antioxidant and anti-inflammatory actions, as well as to its cardiovascular, antiproliferative and antimicrobial benefits.<sup>22-24</sup>

A variety of phenolic natural products have been documented for their anti-ulcerogenic activity with an excellent level of stomach protection. In addition to their action as gastroprotective, these antioxidant compounds can be an alternative for the cure of gastric ulcers.<sup>25,26</sup> Results of the current study showed that animals pre-treated with sidr and omeprazole considerably reduced ulcer area formation compared to animal group pre-treated with only 5% Tween 80 (vehicle). Sidr honey at doses of 100, 250

and 500 mg/kg b.w., significantly ( $P<0.05$ ) inhibited ulcer formation by 78.42%, 85.69% and 92.53%, respectively, as depicted in Table 1 and Figure 1, respectively. As shown in Table 1, ulcer control group produced low mucus content of gastric mucosa, while various doses of sidr honey increased significantly ( $P<0.05$ ) the mucus production. On the other hand, the animal groups pre-treated with sidr honey showed increase in the pH of the gastric juice. The fact that acid gastric juice plays an important role in the genesis of peptic ulcer is supported by clinical, pathological and laboratory-based evidence.<sup>27</sup>

Microscopic evaluation was used to assess the anti-ulcer activities of sidr honey. Histological observation of the ulcer control group pre-treated only with 5% Tween 80, showed highly extensive gastric lesion, submucosal edema and leucocytes infiltration. Pre-treatment with sidr honey



**Figure 2:** Histopathological evaluation.

Results showed that rats pre-treated with sidr honey at doses of 100, 250 & 500 mg/kg (photo 2C, 2D & 2E, respectively) and omeprazole (20 mg/kg, photo 2B) improved the histopathology compared to rats pre-treated with only vehicle (ulcer control group, Figure 2A) (H and E stain; 100x).

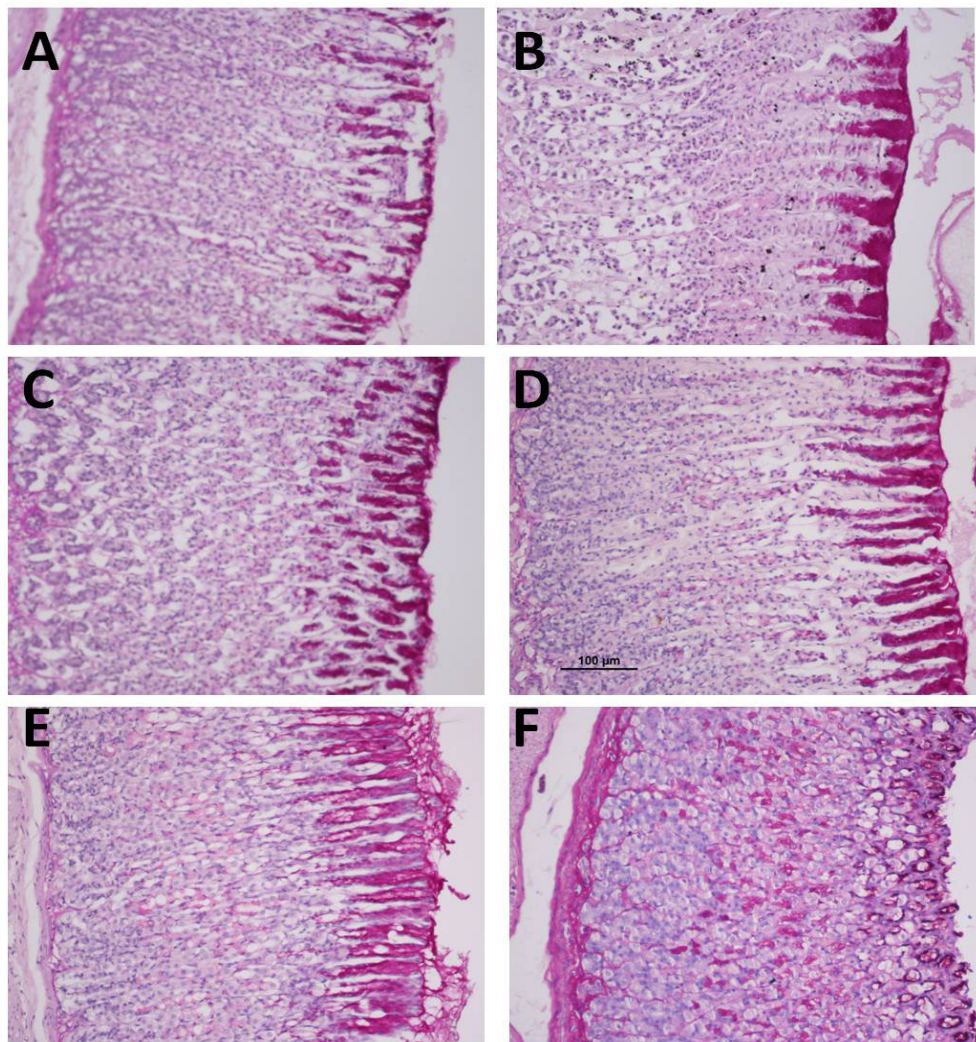
(100, 250 and 500 mg/kg) and omeprazole have relatively better protection as seen by decreasing ulcer area, reduction or complete absence of edema and leucocytes infiltration as shown in Figure 2. A recent study by Rafatullah demonstrated that the administration of Saudi Sidr honey prevented histomorphological lesions triggered by carbon tetrachloride in experimental rats. This protective effect of sidr honey was suggested to be through the presence of antioxidative compounds.<sup>28</sup> On the other hand, treatment of animals with sidr honey resulted in to the expansion of a substantial continuous PAS-positive mucous layer that lining the entire gastric mucosal surface noted as a bright-purple-stained area lining the mucosa as shown in Figure 3.

A previous report, on the role of mitochondrial energy charge in the etiology of ethanol-induced gastric mucosal injury, was published previously.<sup>29</sup> In response to increase

level o free radicals, mitochondrial membrane leaking leads to the upregulation of apoptosis associated protein (Bax, proapoptotic factor). The pathological changes in mitochondria are positively related to ethanol exposure. As mentioned above, ethanol-induced gastric mucosal injury is related to oxidative stress, which disturbs the energy metabolism of mitochondria and plays a critical role in the pathogenesis of ethanol-induced gastric mucosal injury. The present study showed that pre-treatment with sidr honey led to the down-regulation of Bax as shown in Figure 4. These observations suggest the antiapoptotic effect of sidr honey against ethanol induced cell injury.

Phenolic compounds display a number of biological activities in the gastrointestinal tract, acting as antisecretory, cytoprotective, and antioxidant agents. The antioxidant activities of these natural ingredients have been widely





**Figure 3:** PAS staining for the evaluation of mucus production.

Results showed that rats pre-treated with 4-hydroxybenzoic acid at doses of 100, 250 & 500 mg/kg (photo 3C, 3D & 3E, respectively) and omeprazole (20 mg/kg, photo 3B) showed more PAS-positive mucus as compared to those pre-treated with only Tween80 (ulcer control group, Figure 3A) (100x).

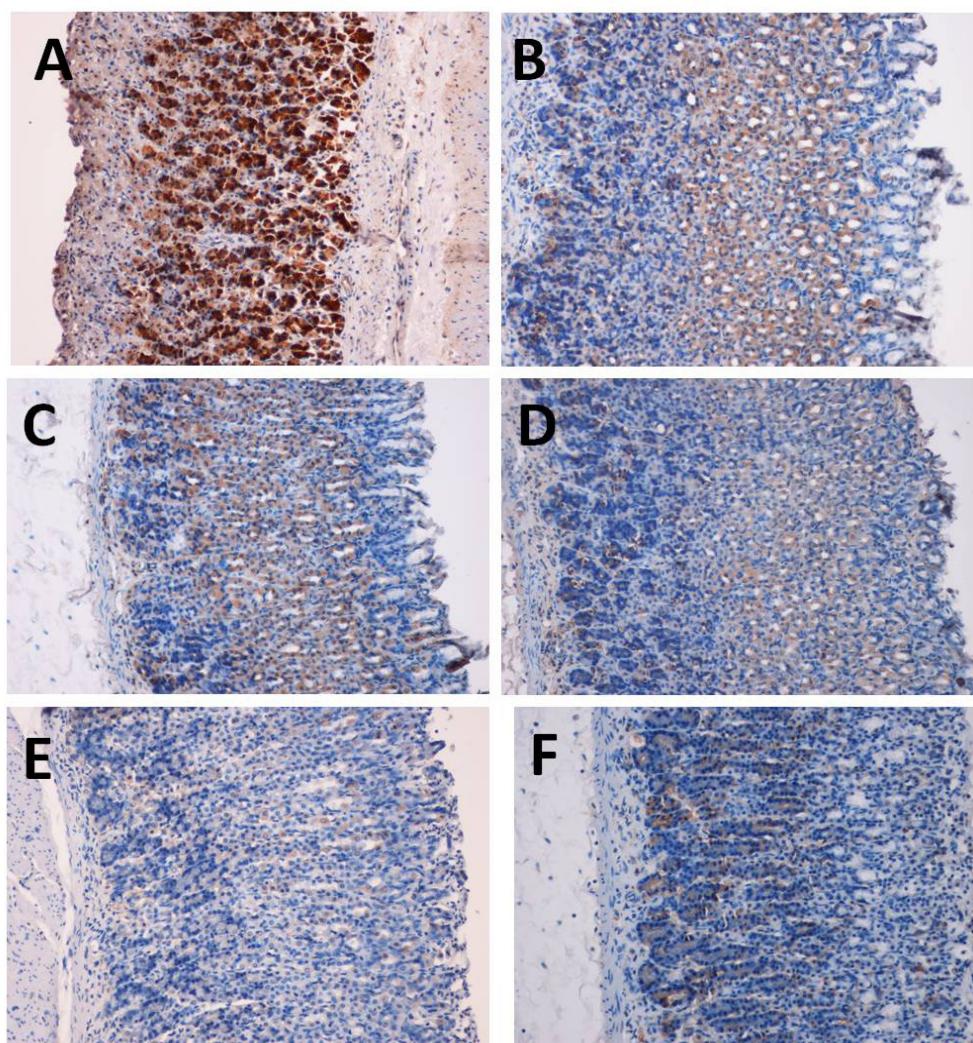
**Table 2: Effect of sidr honey of glutathione (GSH) and malondehyde (MDA) levels**

Animal group	pretreatment (5ml/kg)	GSH	MDA (µmol/g tissue)
I	Ulcer control	0.7 <sup>a</sup> ±0.10	28 <sup>a</sup> ±0.18
II	Omeprazole (20 mg/kg)	8.3 <sup>b</sup> ±1.29	2.4 <sup>b</sup> ±0.26
III	Sidr Honey (100 mg/kg)	4.9 <sup>c</sup> ±0.38	2.9 <sup>b</sup> ±0.13
IV	Sidr Honey (250 mg/kg)	8.5 <sup>b</sup> ±1.02	1.2 <sup>c</sup> ±0.02
V	Sidr Honey (500 mg/kg)	15.1 <sup>c</sup> ±0.49	0.48 <sup>d</sup> ±0.11
VI	Normal control	7.71 <sup>b</sup> ±0.92	0.5 <sup>d</sup> ±0.14

Values are presented as mean ± SEM of five rats in each group. Groups with different alphabets are statistically different.

investigated by many researchers, but it has become clear that their mechanisms of action go beyond the modulation of oxidative stress.<sup>31-33</sup> Deficiency of GSH within the body organs can lead to tissue injury and malfunction.<sup>34</sup> In the present investigation, GSH was remarkably ( $P<0.01$ ) decreased in ulcer group than the normal group. The treatment of animals with the sidr honey restored significantly ( $P<0.01$ ) the GSH levels depletion caused by ethanol administration. These findings are in accordance with earlier reports as GSH levels were significantly depleted in gastric homogenate of rats, when exposed with ethanol.<sup>35,36</sup> Pretreatment of rats with sidr honey replenished GSH level as compared with ethanol only treated animals, suggesting the ameliorative effects of sidr honey. Moreover, ethanol was reported to induced





**Figure 4:** Immunohistochemical staining of rat gastric tissues with Bax primary antibody (100x).

lipid peroxidation in the gastric wall of induced animals.<sup>37</sup> In the present study, ulcer control group showed the highest malondialdehyde (MDA) level, an indicator of lipid peroxidation, than the other groups. Gastric MDA level significantly ( $P < 0.05$ ) dropped after sidr honey administration. Results for MDA and GSH are showing in Table 2. The antioxidant mechanism of Sidr honey was further analyzed using phytochemical studies. Saudi Sidr honey in this study, demonstrated high total phenolic and flavonoid contents (85.4 mg GAE/100g and 42.5 QAE/100g). The <sup>1</sup>H-NMR of sidr honey showed the presence of methyl, methylene and aromatic CH. However, analysis also showed the presence of hydroxyl group peak as well.

### CONCLUSION

In conclusion, sidr honey remarkably and dose-dependently protects the gastric mucosa against ethanol-triggered

damage. The antioxidant activity of this natural substance, through the induction of cellular antioxidant protection, is a pointer for scavenging the free radicals formed by ethanol. The current findings warrant further research for the introduction of sidr honey as possible defensive and remedial agent for gastric ulcer that caused by different etiologies. Authors are currently analyzing the phytochemical content of sidr honey.

### CONFLICT OF INTEREST

Authors declare no conflict of interest.

### ACKNOWLEDGMENTS

This research was graciously supported by the Scientific Chair for Prophetic Medicine and Scientific Miracle (MABL Chair).

## REFERENCES

- Zumla A, Lulat A. Honey--a remedy rediscovered. *Journal of the Royal Society of Medicine* 1989; 82(7): 384.
- El-Soud A, Helmy N. Honey between traditional uses and recent medicine. *Macedonian Journal of Medical Sciences* 2012; 5(2): 205-14.
- Halawani EM, Shohayeb MM. Shaoka and Sidr honeys surpass in their antibacterial activity local and imported honeys available in Saudi markets against pathogenic and food spoilage bacteria. *Aust J Basic Appl Sci.* 2011; 5(4): 187-91.
- Al-Mamary M, Al-Meerri A, Al-Habori M. Antioxidant activities and total phenolics of different types of honey. *Nutrition Research* 2002; 22(9): 1041-7.
- Altman N. *The Honey Prescription: The Amazing Power of Honey as Medicine: Healing Arts Press*; 2010.
- Alqurashi AEAM, Alamin M. Antibacterial activity of Saudi honey against Gram negative bacteria. *Journal of Microbiology and Antimicrobials* 2013; 5(1): 1-5.
- Chepulis L. *Healing Honey: A Natural Remedy for Better Health and Wellness: Brown Walker Press*; 2008.
- Cotte J-F, Casabianca H, Chardon S, Lheritier J, Grenier-Loustalot M-F. Chromatographic analysis of sugars applied to the characterisation of monofloral honey. *Analytical and bioanalytical chemistry* 2004; 380(4): 698-705.
- Al-Waili NS, Salom K, Butler G, Al Ghamdi AA. Honey and microbial infections: a review supporting the use of honey for microbial control. *Journal of medicinal food* 2011; 14(10): 1079-96.
- Molan PC. Why honey is effective as a medicine. 1. Its use in modern medicine; 1999.
- Ajibola A, Chamunorwa JP, Erlwanger KH. Nutraceutical values of natural honey and its contribution to human health and wealth. *Nutrition & Metabolism* 2012; 9(1): 1-12.
- Hegazi AG, Allah FMA. Antimicrobial Activity of Different Saudi Arabia Honeys *Global Veterinaria* 2012; 9(1): 53-9.
- Shimoyama AT, Santin JR, Machado ID, e Silva AMdO, de Melo ILP, Mancini-Filho J, *et al.* Antilcerogenic activity of chlorogenic acid in different models of gastric ulcer. *Naunyn-Schmiedeberg's archives of pharmacology* 2013; 386(1): 5-14.
- Izuhara C, Takayama S, Itayama M, Hoshin N, Yoshida Y, Takeuchi K. Animal Model for Evaluating Gastric Bleeding and Ulcerogenic Response Induced by Aspirin plus Clopidogrel. *Front Gastrointest Res* 2012; 30(1): 87-96.
- Potrich FB, Allemand A, da Silva LM, dos Santos AC, Baggio CH, Freitas CS, *et al.* Antilcerogenic activity of hydroalcoholic extract of *Achillea millefolium* L.: Involvement of the antioxidant system. *Journal of ethnopharmacology* 2010; 130(1): 85-92.
- Tan PV, Nyasse B, Dimo T, Mezui C. Gastric cytoprotective anti-ulcer effects of the leaf methanol extract of *Ocimum suave* (Lamiaceae) in rats. *Journal of ethnopharmacology* 2002; 82(2): 69-74.
- Njar VCO, Adesanwo JK, Raji Y. Methyl angolenate: The antiulcer agent from the stem bark of *Entandrophragma angolense*. *Planta Medica-Journal of Medicinal Plant Research* 1995; 61(1): 91-2.
- Behmer OA. *Manual de técnicas para histologia normal e patológica: EDART/USP*; 1976.
- Kaur G, Arora D. Antibacterial and phytochemical screening of *Anethum graveolens*, *Foeniculum vulgare* and *Trachyspermum ammi*. *BMC Complementary and Alternative Medicine* 2009; 9(1): 30-9.
- Sumbul S, Ahmad MA, Mohd A. Role of phenolic compounds in peptic ulcer: An overview. *Journal of Pharmacy and Bioallied Sciences* 2011; 3(3): 361-7.
- El-Abhar HS. Coenzyme Q10: A novel gastroprotective effect via modulation of vascular permeability, prostaglandin E<sub>2</sub>, nitric oxide and redox status in indomethacin-induced gastric ulcer model. *European journal of pharmacology* 2010; 649(1): 314-9.
- M Alvarez-Suarez J, Giampieri F, Battino M. Honey as a Source of Dietary Antioxidants: Structures, Bioavailability and Evidence of Protective Effects Against Human Chronic Diseases. *Current medicinal chemistry* 2013; 20(5): 621-38.
- Abdelaziz I, Elhabiby M, Ashour A. Toxicity of cadmium and protective effect of bee honey, vitamins C and B complex. *Human and experimental toxicology* 2013; 32(4): 362-70.
- Mohamed M, Sulaiman SA, Sirajudeen KNS. Protective effect of honey against cigarette smoke induced-impaired sexual behavior and fertility of male rats. *Toxicology and Industrial Health* 2013; 29(3): 264-71.
- Luiz-Ferreira A, Cola M, Barbastefano V, de-Faria FM, Almeida ABA, Farias-Silva E, *et al.* Healing, Antioxidant and Cytoprotective Properties of *Indigofera truxillensis* in Different Models of Gastric Ulcer in Rats. *International Journal of Molecular Sciences* 2012; 13(11): 14973-91.
- Sindhu ER, Kuttan R. Carotenoid lutein protects rats from gastric ulcer induced by ethanol. *Journal of Basic and Clinical Physiology and Pharmacology* 2012; 23(1): 33-7.
- Malfrather P, Chan FK, McColl KE. Peptic ulcer disease. *The Lancet* 2009; 374(9699): 1449-61.
- Rafatullah S. Attenuation of CCl<sub>4</sub>-Induced Oxidative Stress and Hepatonephrotoxicity by Saudi Sidr Honey in Rats. *Evidence-Based Complementary and Alternative Medicine*; 2013.
- Maity P, Bindu S, Dey S, Goyal M, Alam A, Pal C, *et al.* Melatonin reduces indomethacin-induced gastric mucosal cell apoptosis by preventing mitochondrial oxidative stress and the activation of mitochondrial pathway of apoptosis. *Journal of pineal research* 2009; 46(3): 314-23.
- Higuchi H, Adachi M, Miura S, Gores GJ, Ishii H. The mitochondrial permeability transition contributes to acute ethanol-induced apoptosis in rat hepatocytes. *Hepatology* 2001; 34(2): 320-8.
- Allemand A, Mendes DAGB, Andr  A, Cipriani TR, Dartora N, Marques MCA, *et al.* Ethanolic extract of roots from *Arctium lappa* L. accelerates the healing of acetic acid-induced gastric ulcer in rats: Involvement of the antioxidant system. *Food and Chemical Toxicology* 2012; 51(2): 179-87.
- Ogawa K, Oyagi A, Tanaka J, Kobayashi S, Hara H. The protective effect and action mechanism of *Vaccinium myrtillus* L. on Gastric Ulcer in mice. *Phytotherapy Research* 2011; 25(8): 1160-5.
- Nartey E, Ofosuhen M, Kudzi W, Agbale C. Antioxidant and gastric cytoprotective prostaglandins properties of *Cassia sieberiana* roots bark extract as an anti-ulcerogenic agent. *BMC Complementary and Alternative Medicine* 2012; 12(1): 65-75.
- Cemek M, Yilmaz E, B y kokuroglu ME. Protective effect of *Matricaria chamomilla* on ethanol-induced acute gastric mucosal injury in rats. *Pharmaceutical Biology* 2010; 48(7): 757-63.
- Liu Y, Tian X, Gou L, Fu X, Li S, Lan N, *et al.* Protective effect of L-citrulline against ethanol-induced gastric ulcer in rats. *Environmental Toxicology and Pharmacology* 2012; 34(2): 280-7.
- Luiz-Ferreira A, Almeida ACA, Cola M, Barbastefano V, Almeida ABA, Batista LM, *et al.* Mechanisms of the gastric antiulcerogenic activity of *Anacardium humile* St. Hil on ethanol-induced acute gastric mucosal injury in rats. *Molecules* 2010; 15(10): 7153-66.
- Alvarez-Suarez JM, Dekanski D, Risti  S, Radonji  NV, Petronijevi  ND, Giampieri F, *et al.* Strawberry polyphenols attenuate ethanol-induced gastric lesions in rats by activation of antioxidant enzymes and attenuation of MDA increase. *PLoS One.* 2011; 6(10): e25878.